

PROF FERNANDO HENRIQUE ALVES BENEDITO

**ANATOMIA E
PATOLOGIA EM
IMAGENS II**



UniSALESIANO



Exames de imagens

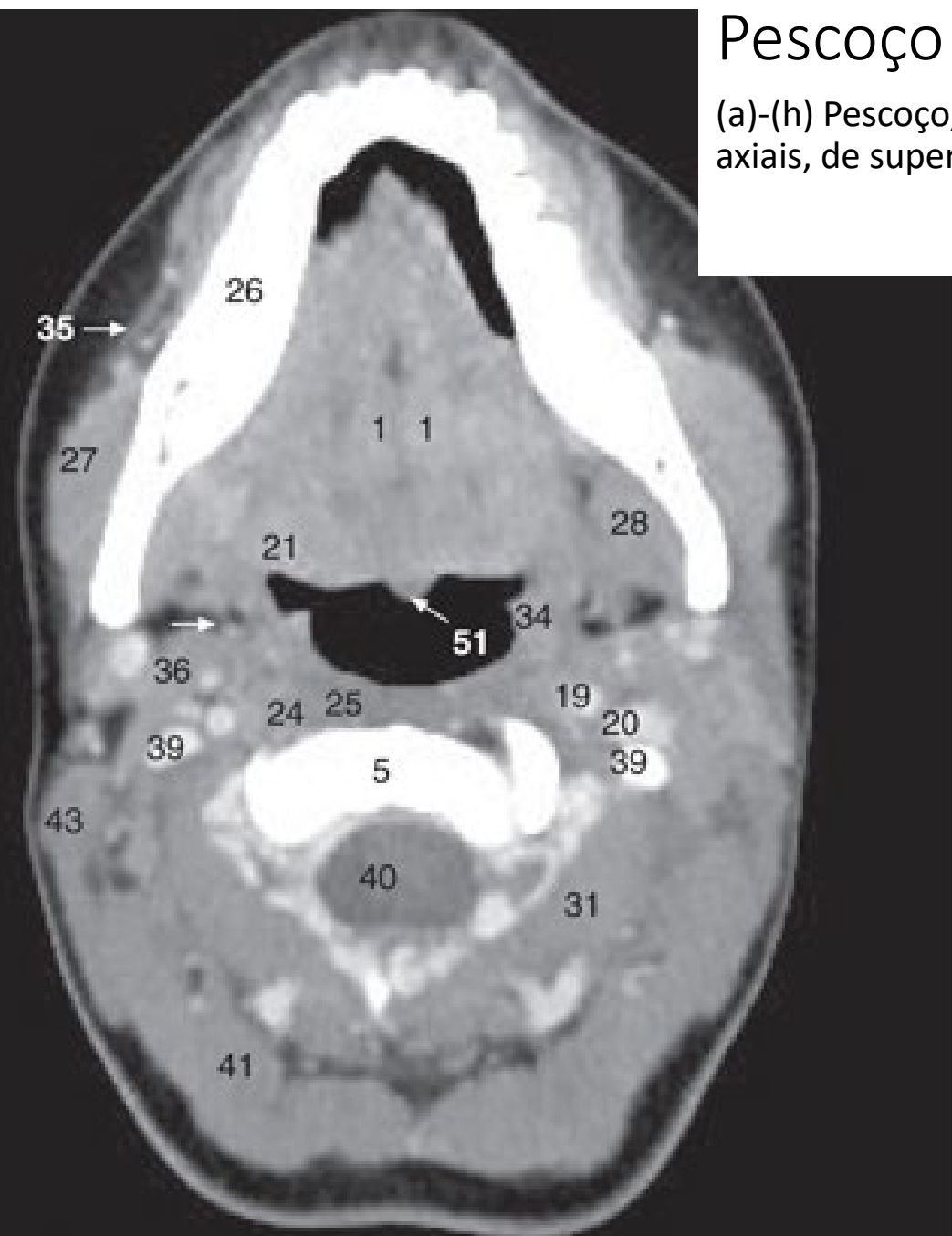
- Encéfalo
- Crânio
- Pescoço
- Coluna vertebral
- Membro superior
- Mama e axila
- Tórax, Pulmões, mediastino
- Vasos do coração
- Abdome
- Pelve
- Ultrassonografia do abdome superior
- Ultrassonografia de abdome e pelve
- Quadril
- Membros inferiores
- Exames funcionais

Exames de imagens

- Encéfalo
- Crânio
- **Pescoço**
- Coluna vertebral e medula espinhal
- Membro superior
- Mama e axila
- Tórax, Pulmões, mediastino
- Vasos do coração
- Abdome
- Pelve
- Ultrassonografia do abdome superior
- Ultrassonografia de abdome e pelve
- Quadril
- Membros inferiores
- Exames funcionais

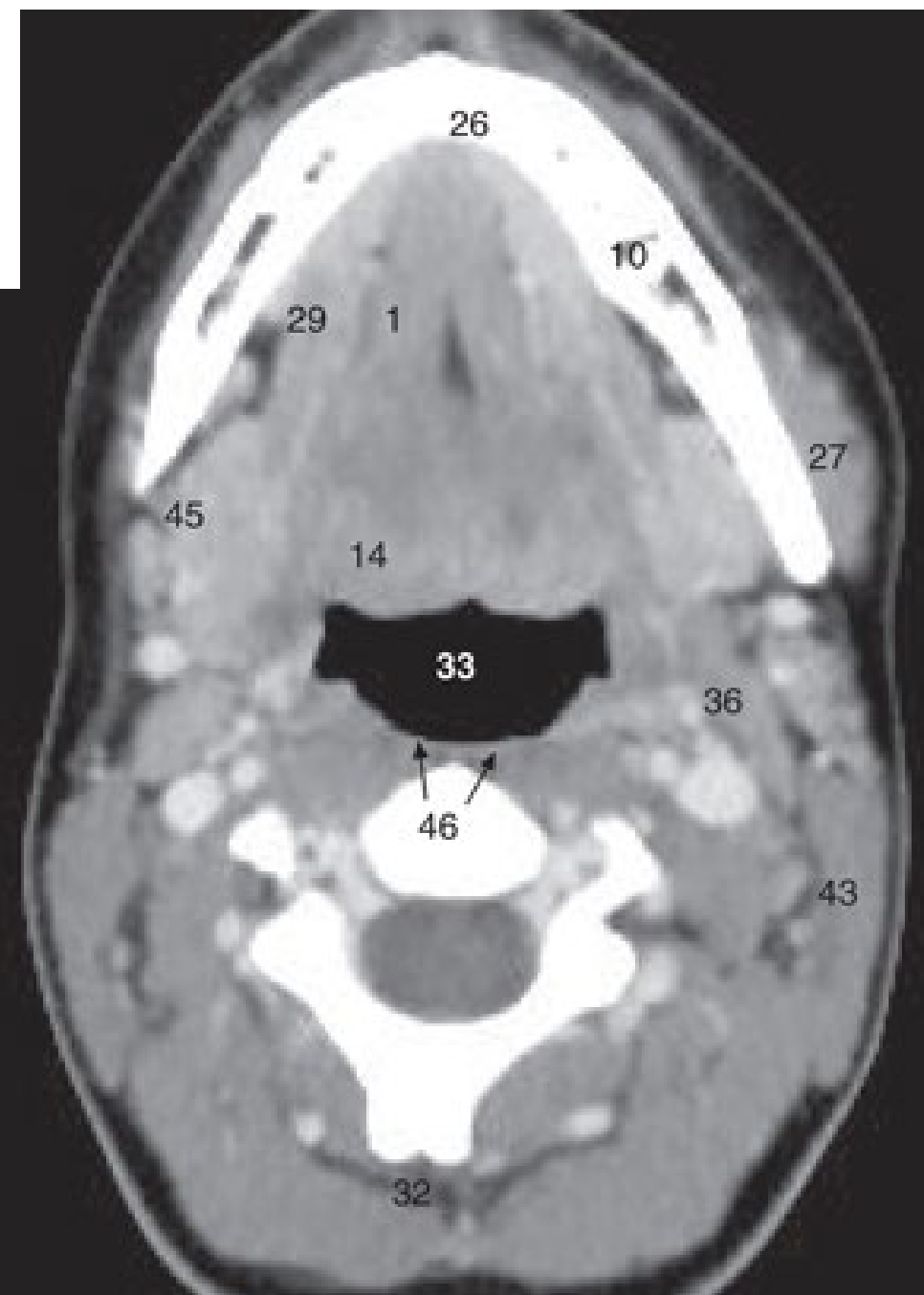
Pescoço

(a)-(h) Pescoço, imagens de TC axiais, de superior a inferior.

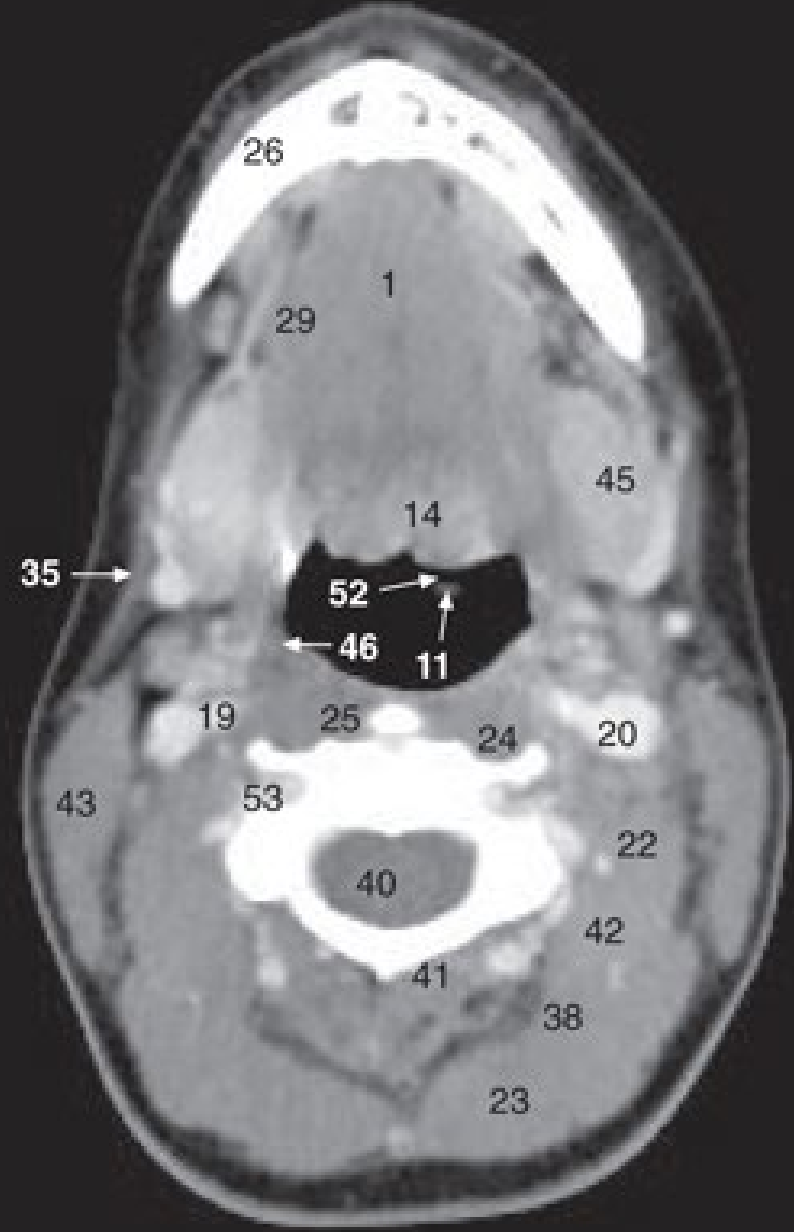


22/05/2020

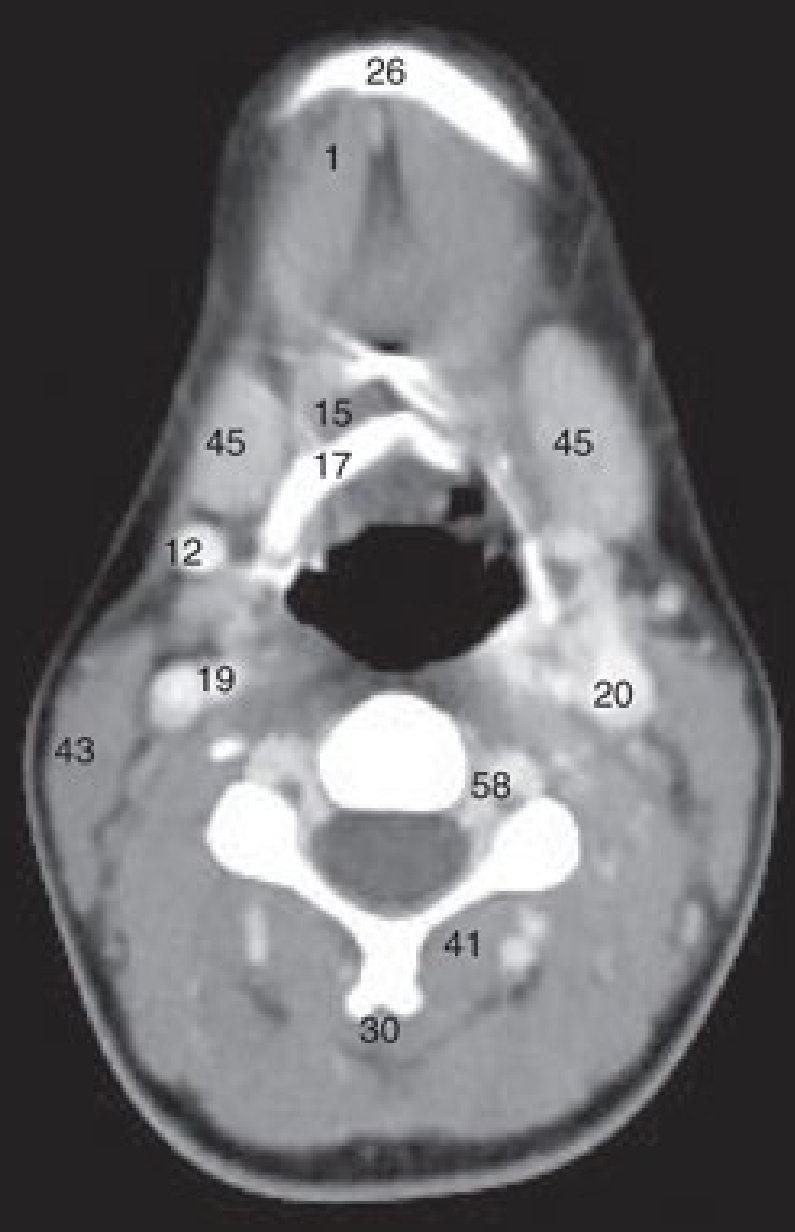
a



b



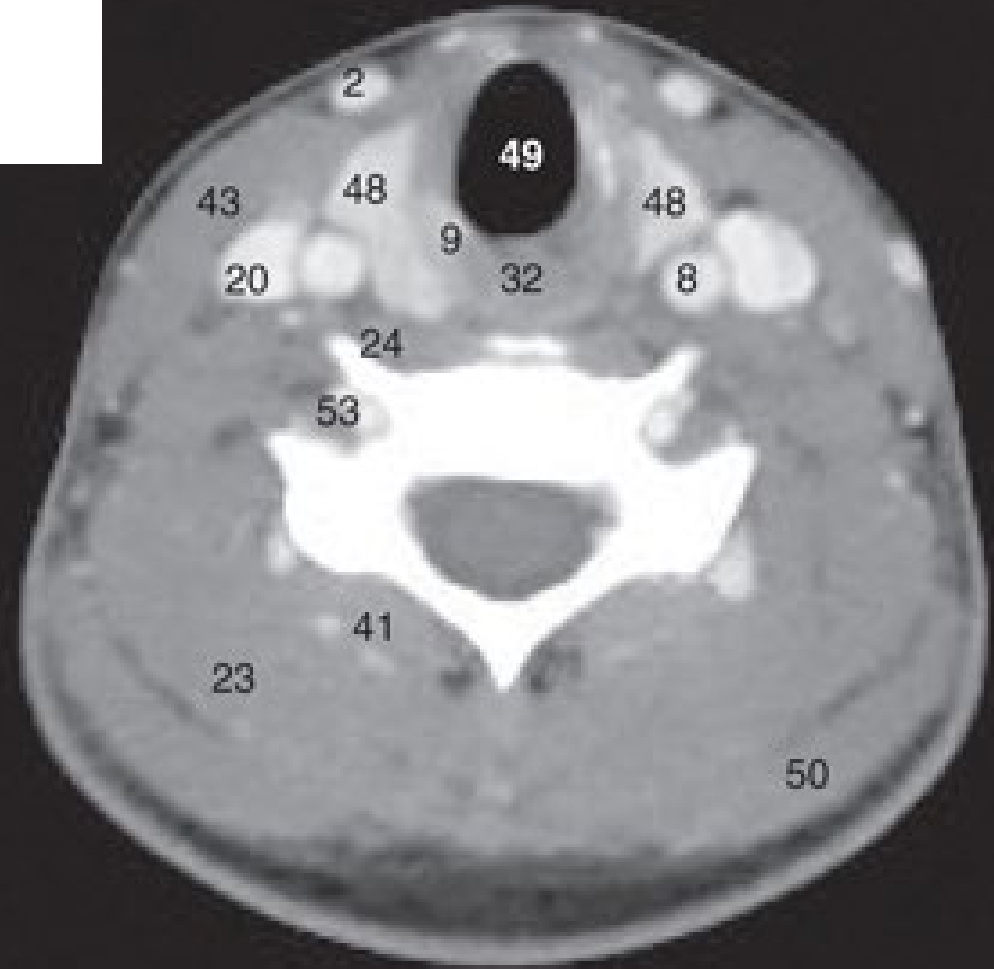
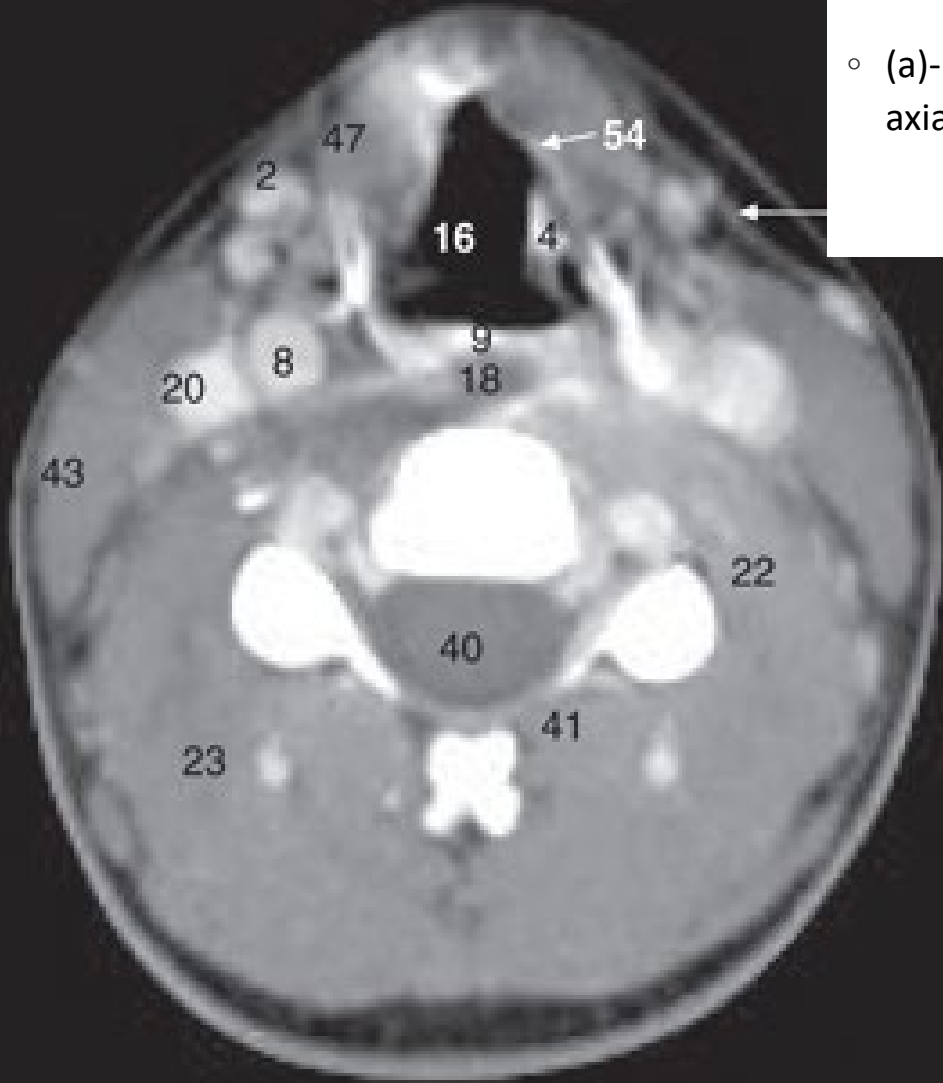
c



d

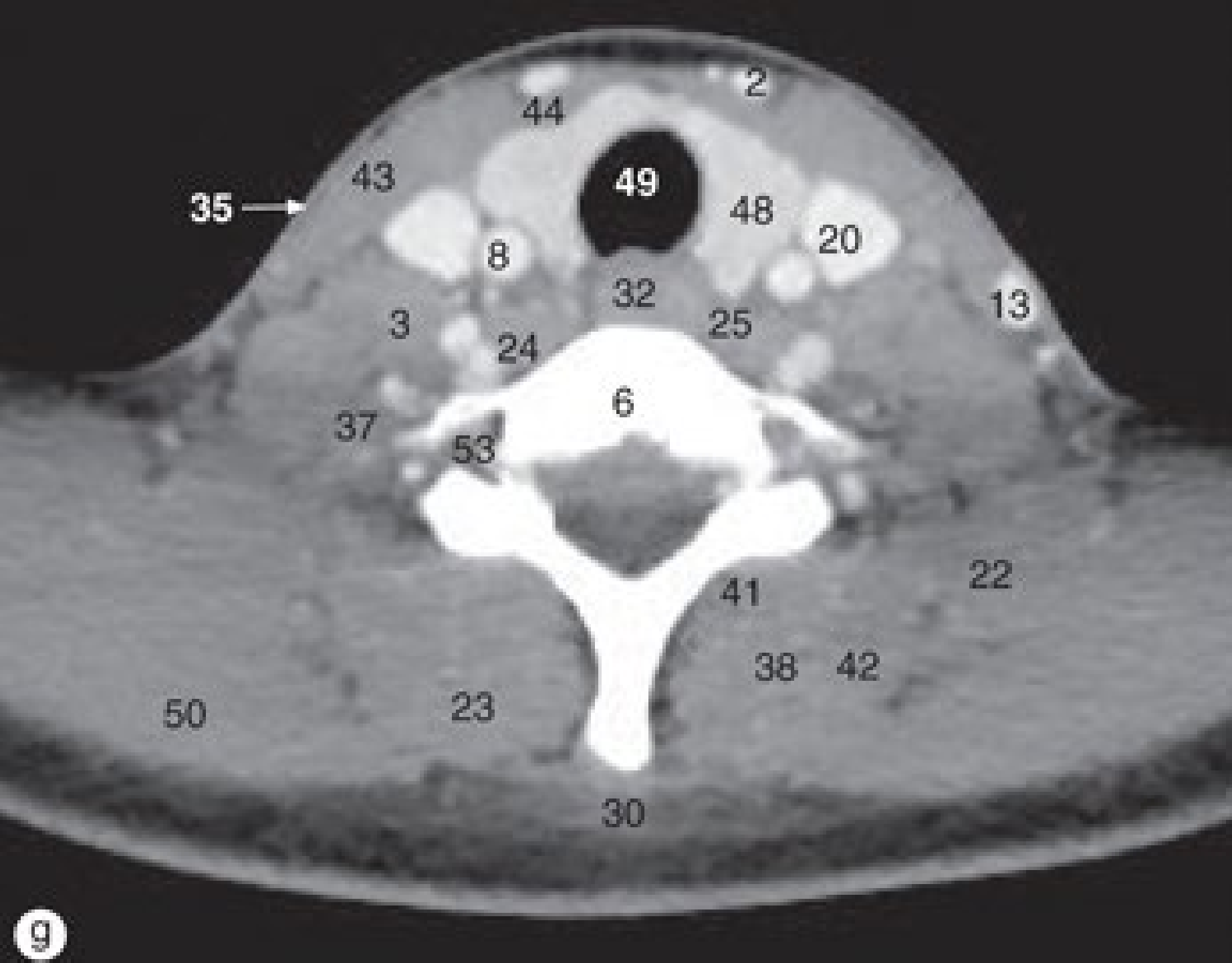
Pescoço

- (a)-(h) Pescoço, imagens de TC axiais, de superior a inferior.



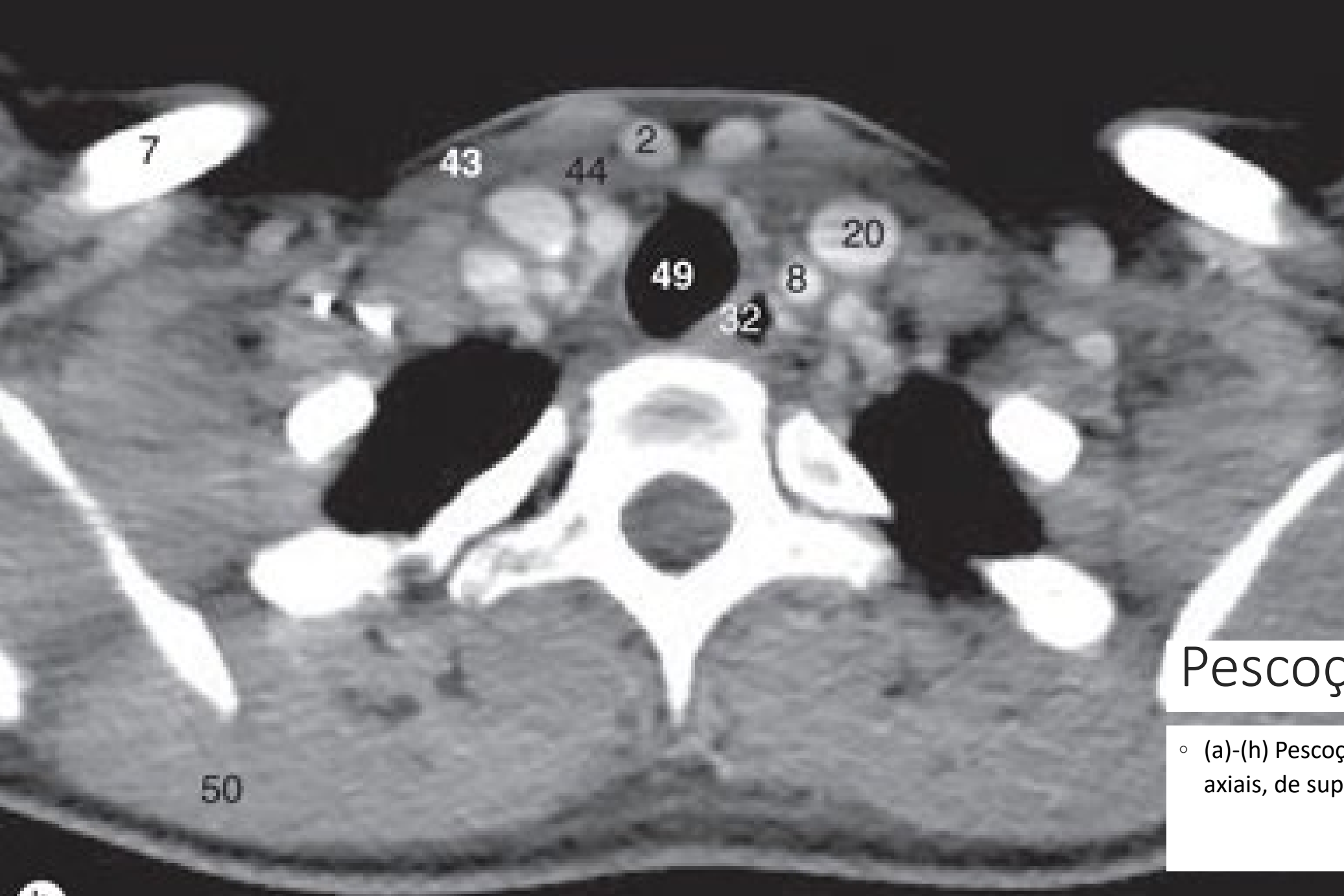
e

f



Pescoço

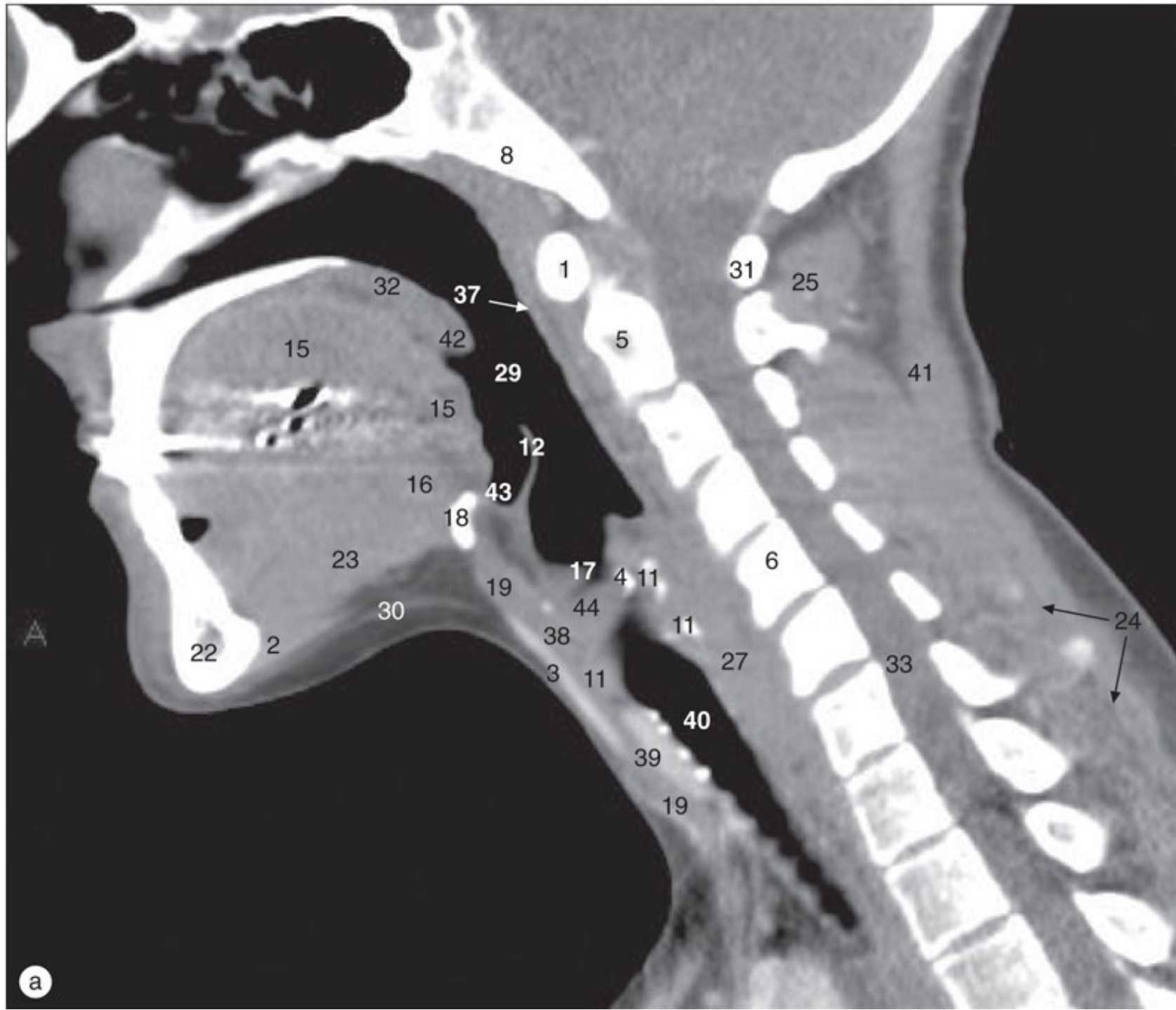- (a)-(h) Pescoço, imagens de TC axiais, de superior a inferior.



Pescoço

- (a)-(h) Pescoço, imagens de TC axiais, de superior a inferior.

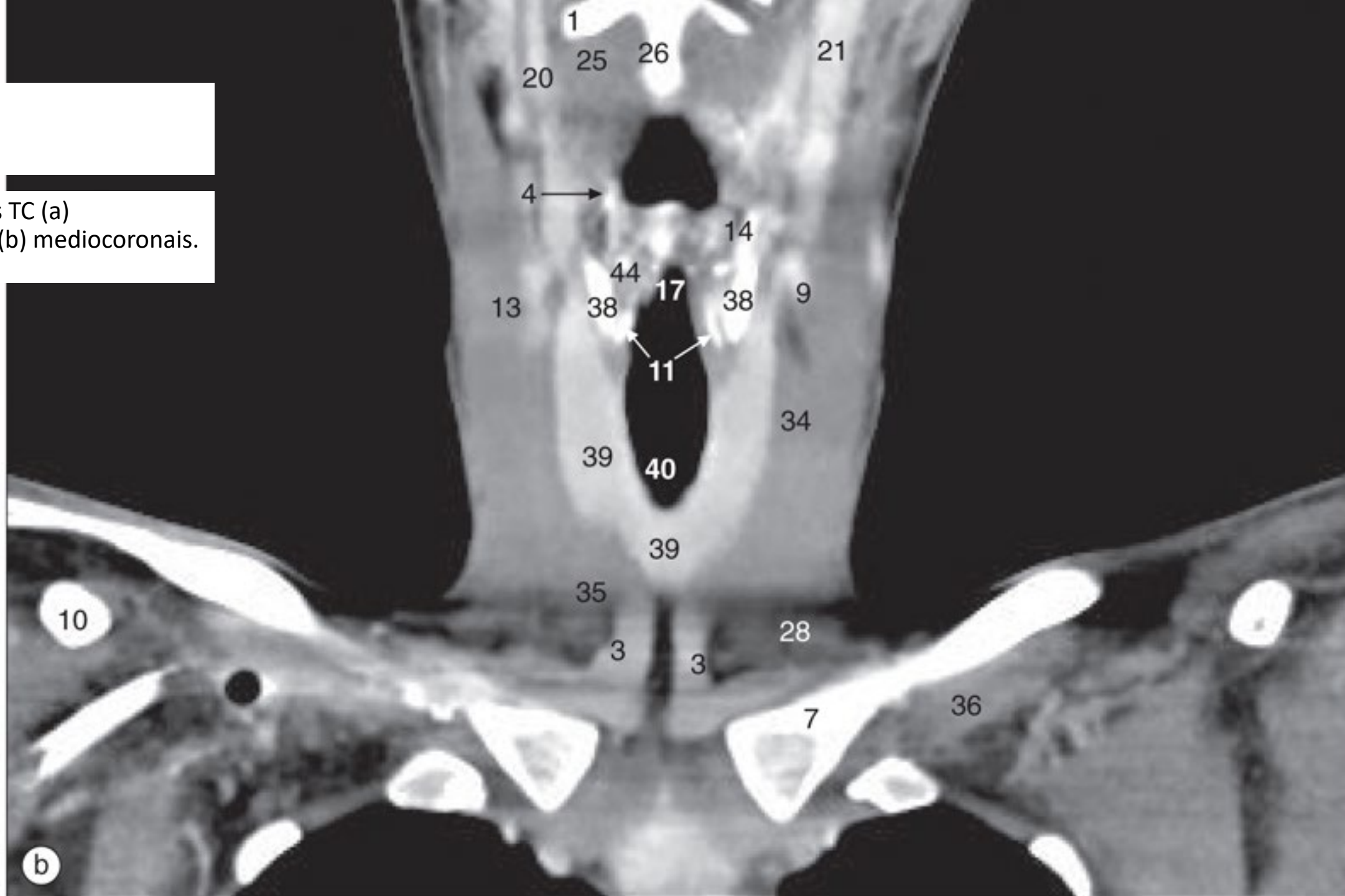
h

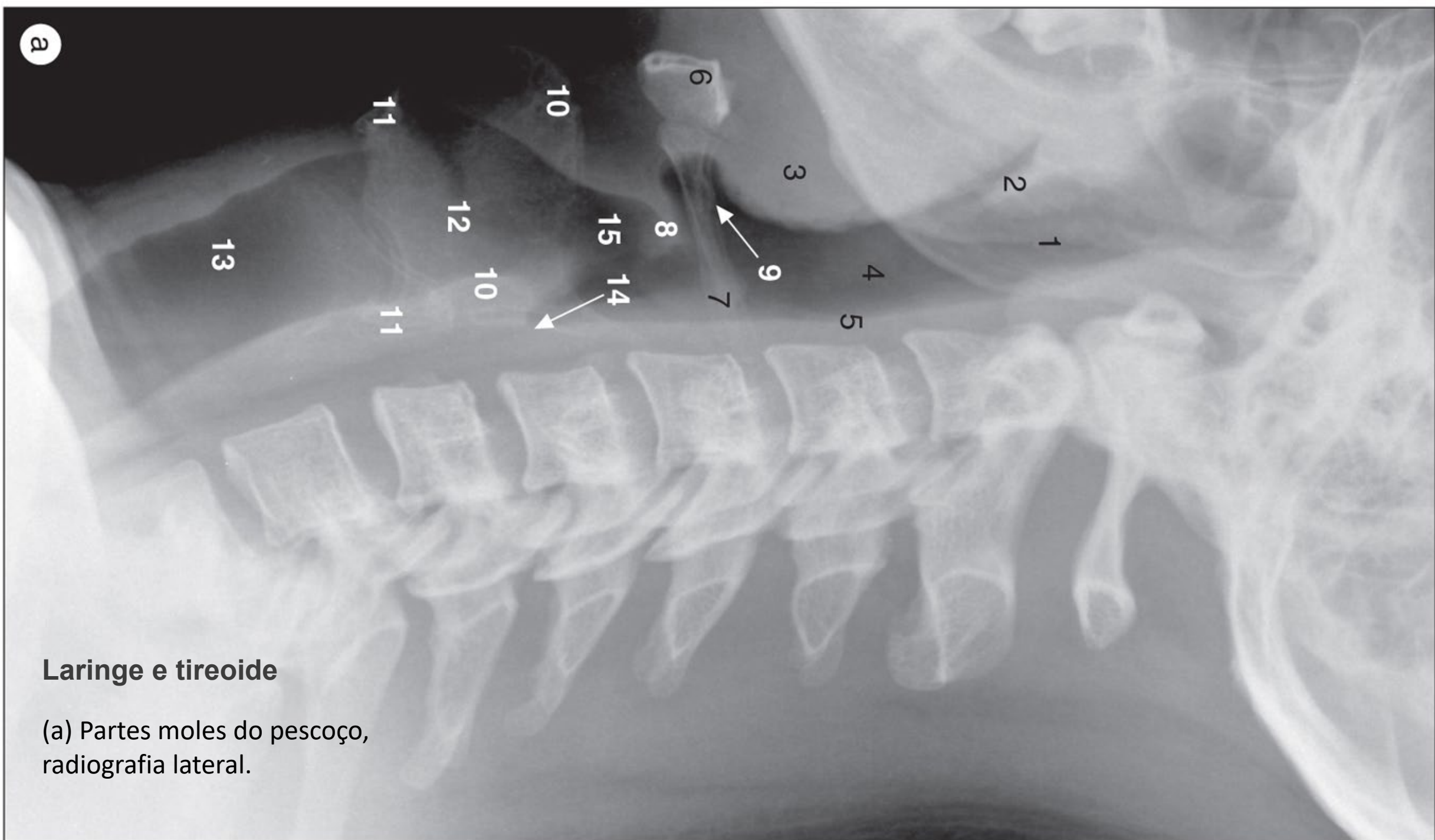


a

Pescoço

Pescoço, imagens TC (a) mediosagitais e (b) mediocoronais.





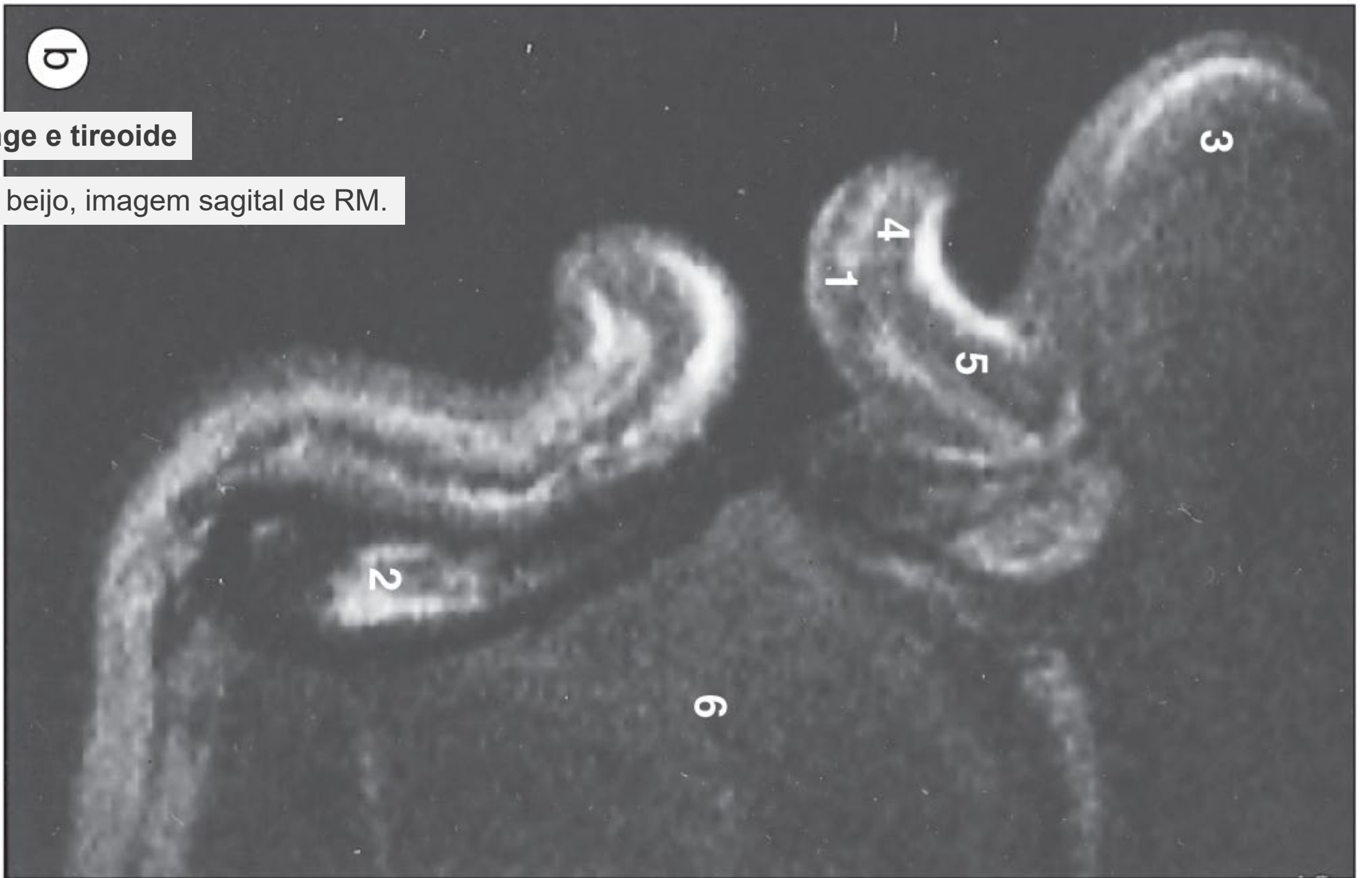
Laringe e tireoide

(a) Partes moles do pescoço,
radiografia lateral.

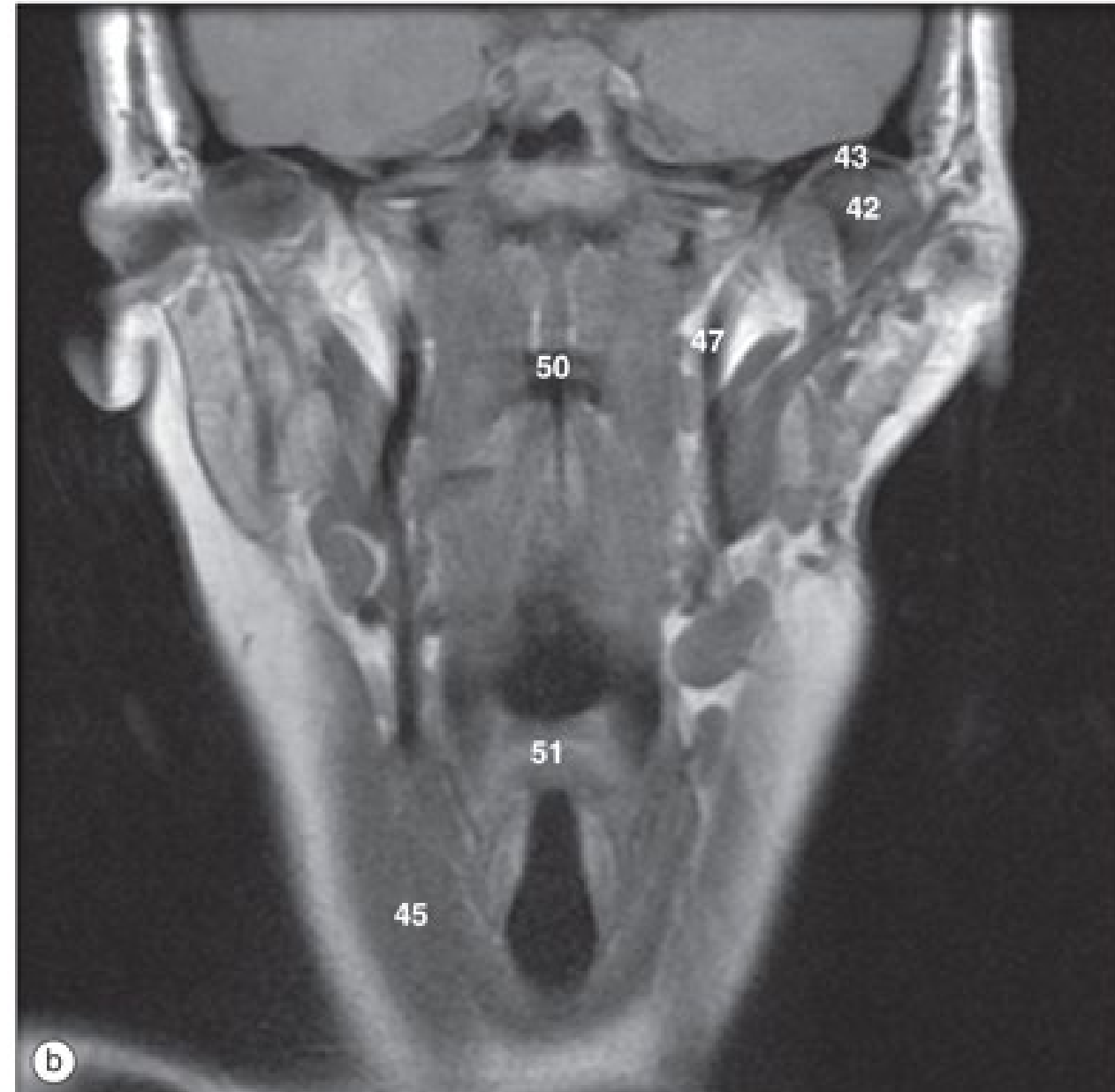
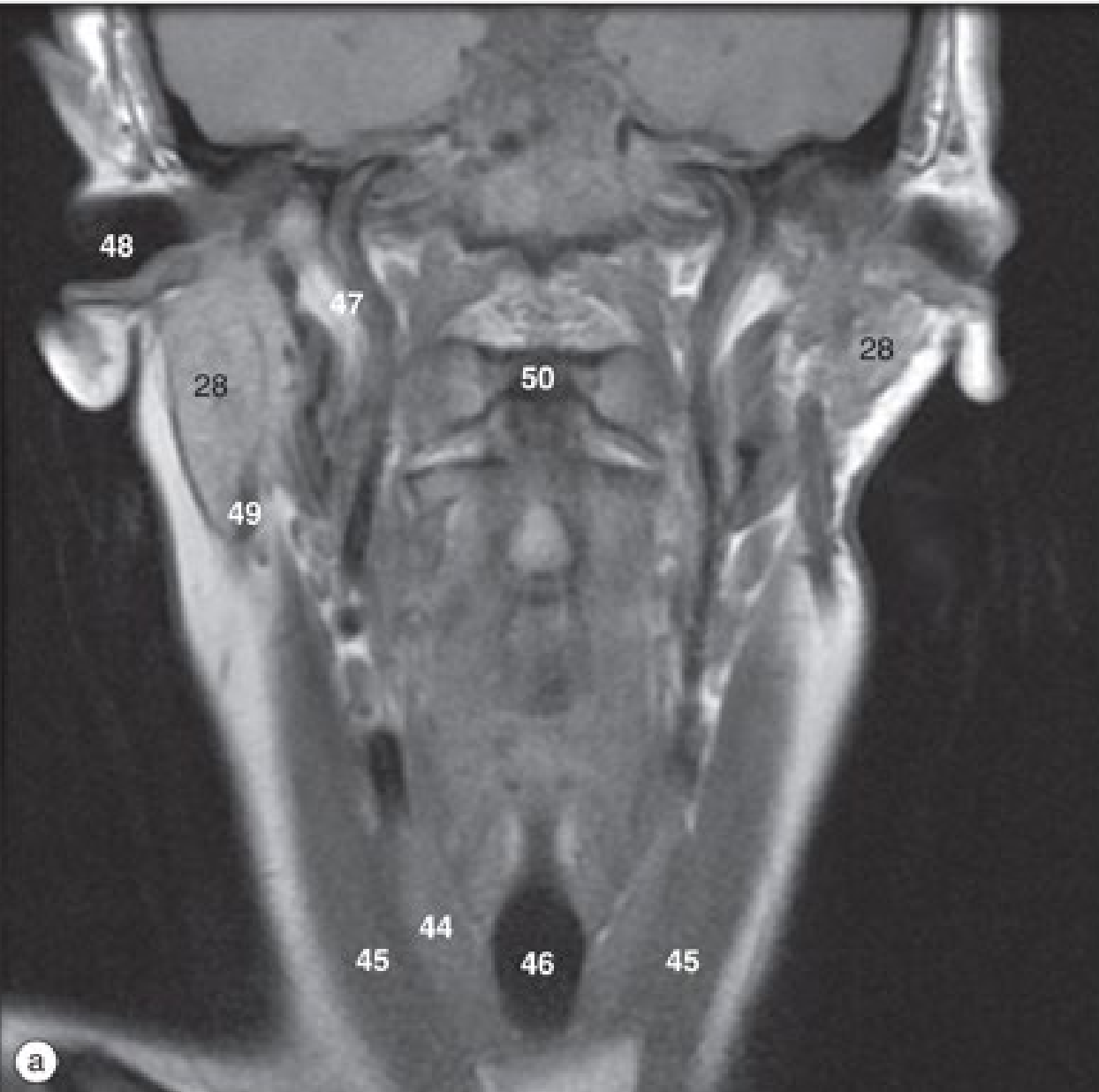b

Laringe e tireoide

(b) O beijo, imagem sagital de RM.



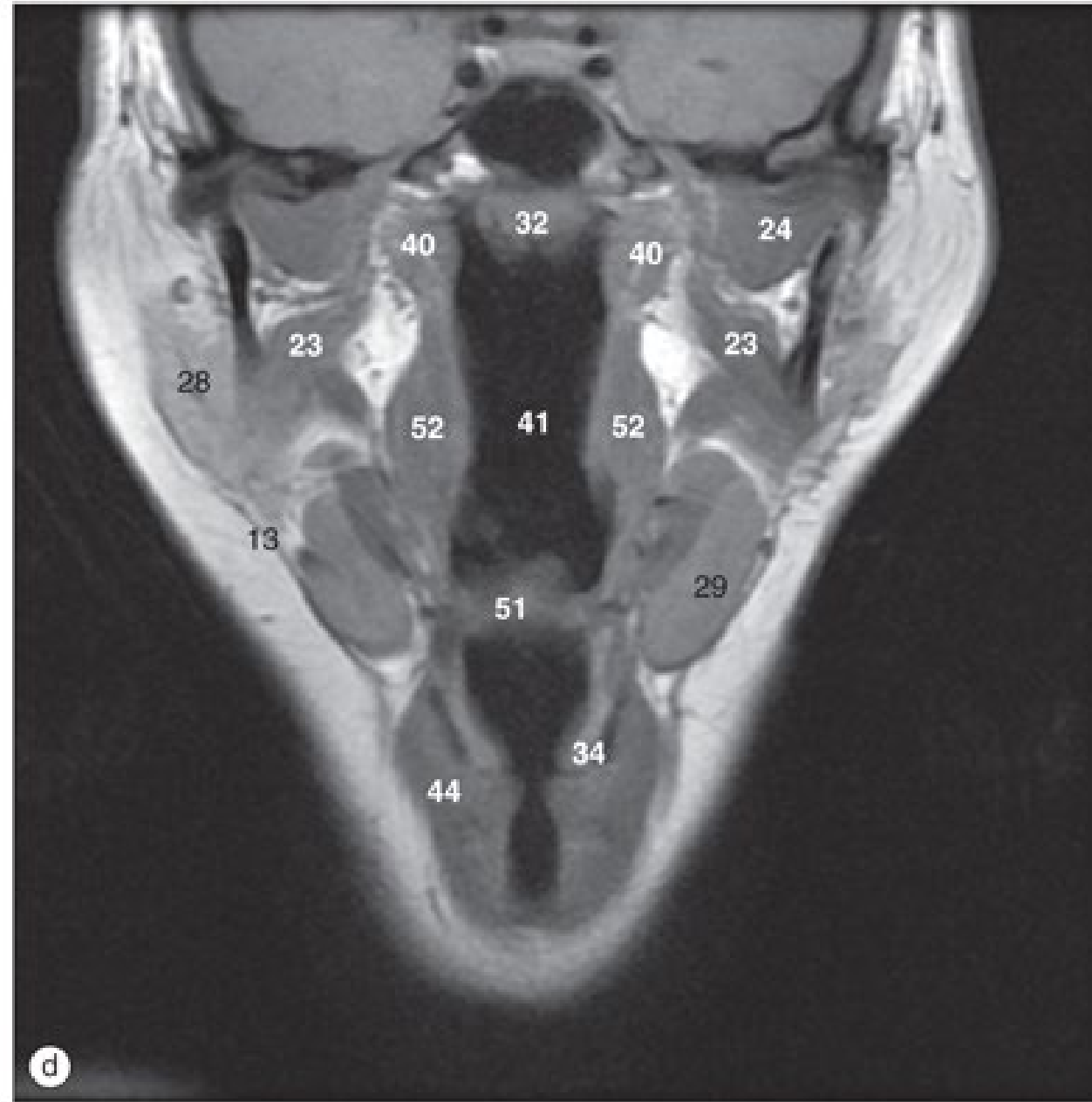
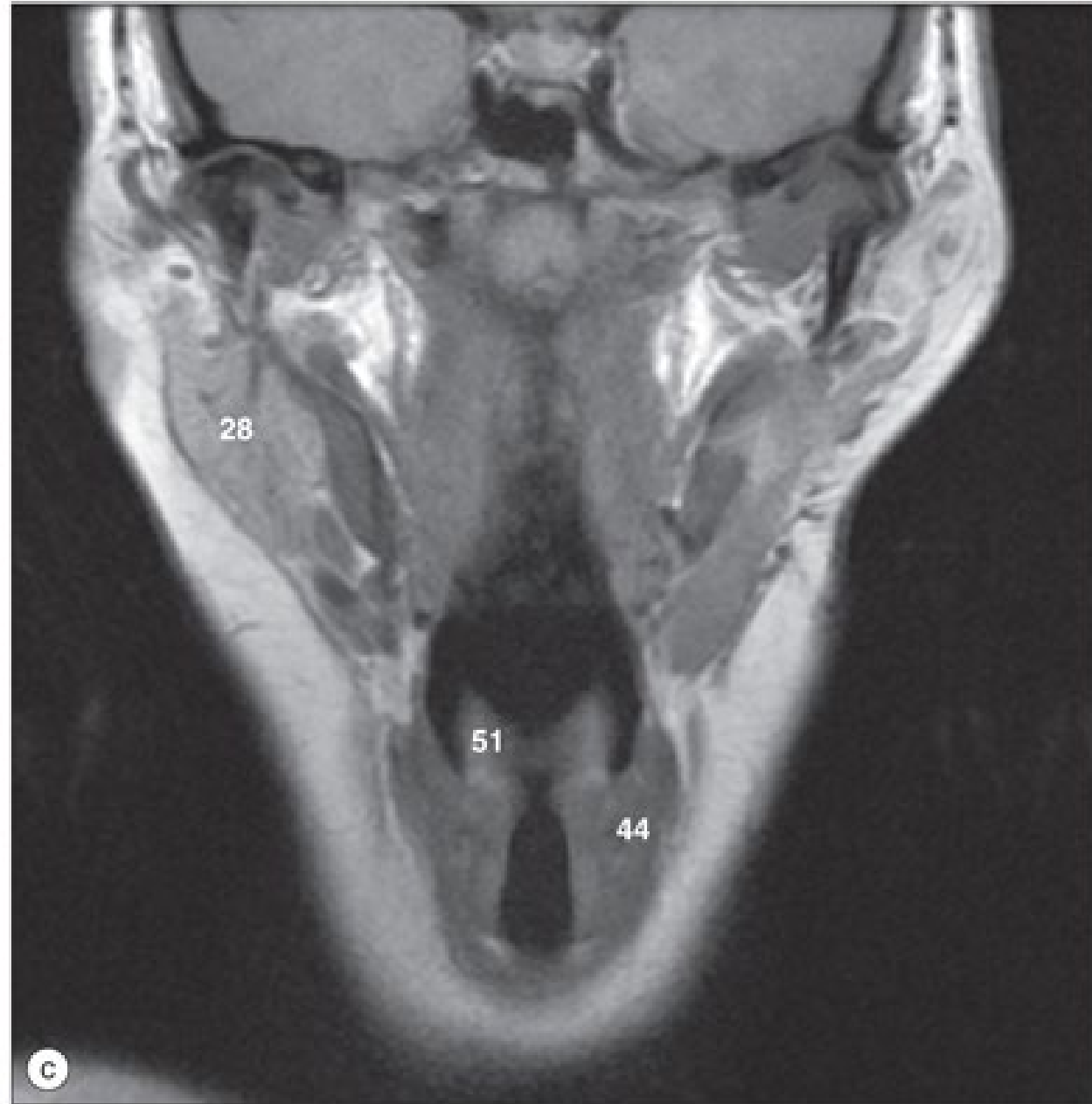
Faringe



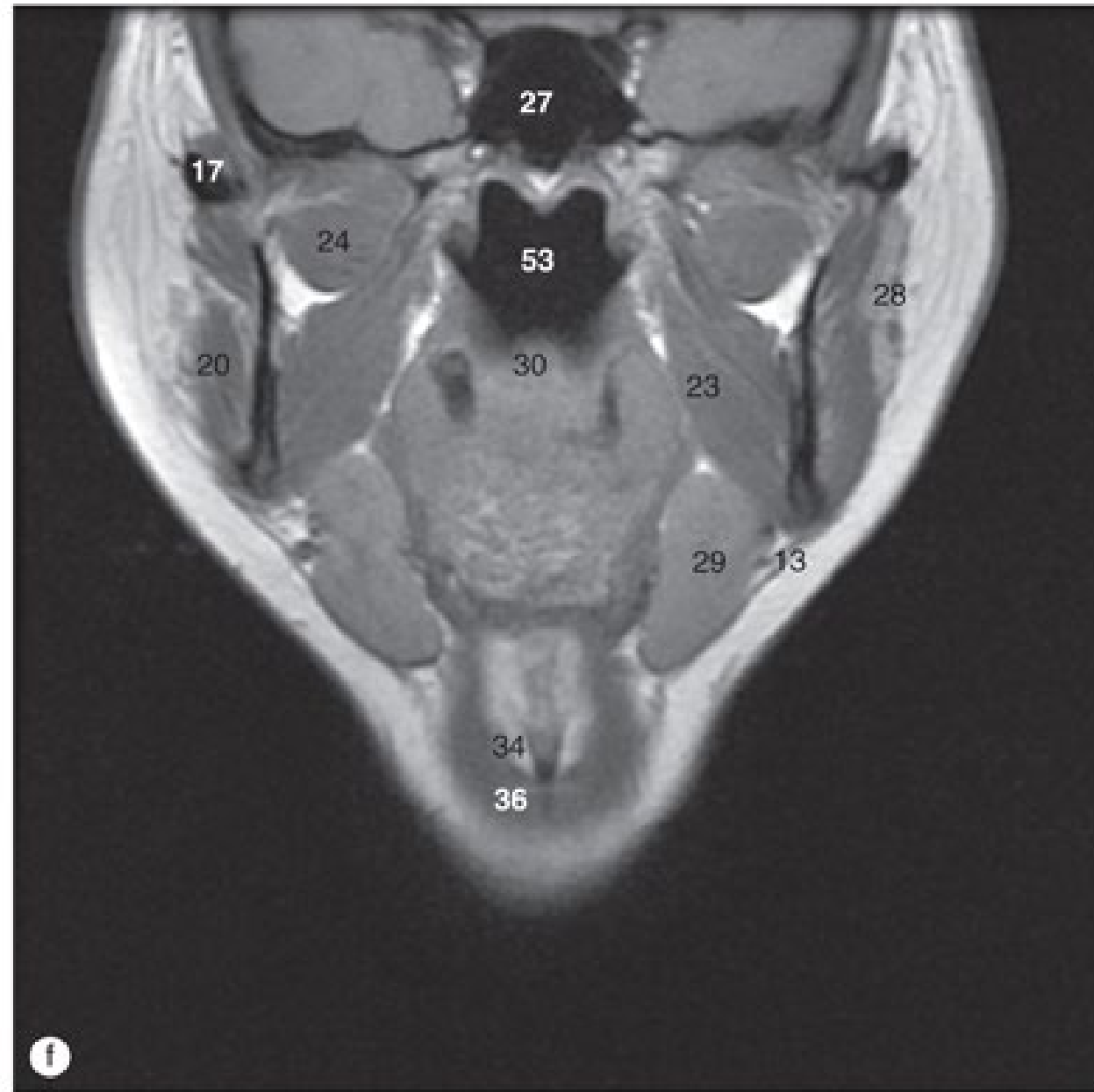
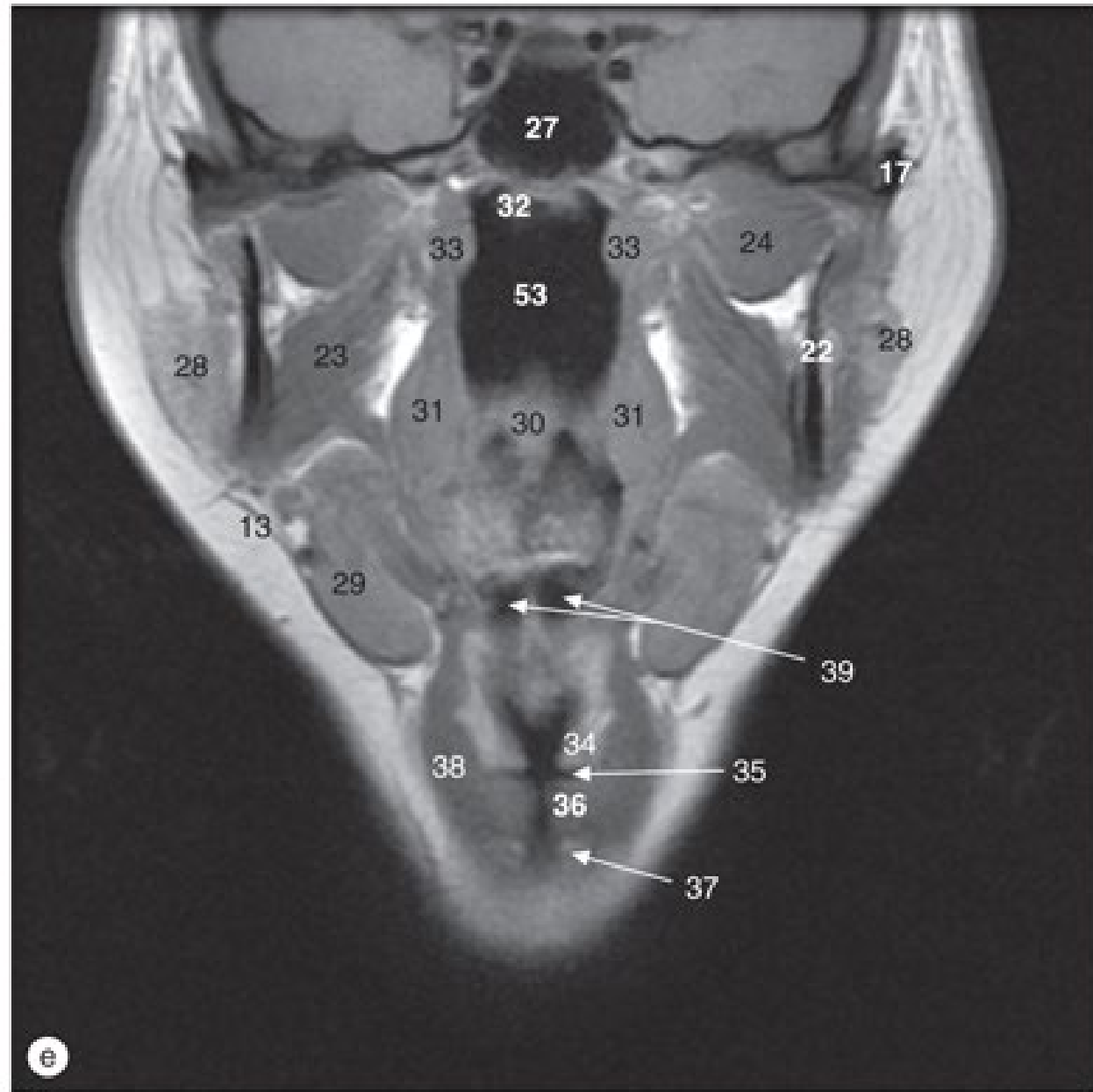
22/05/2020

(a)-(I) Faringe, imagens coronais de RM, de posterior a anterior.

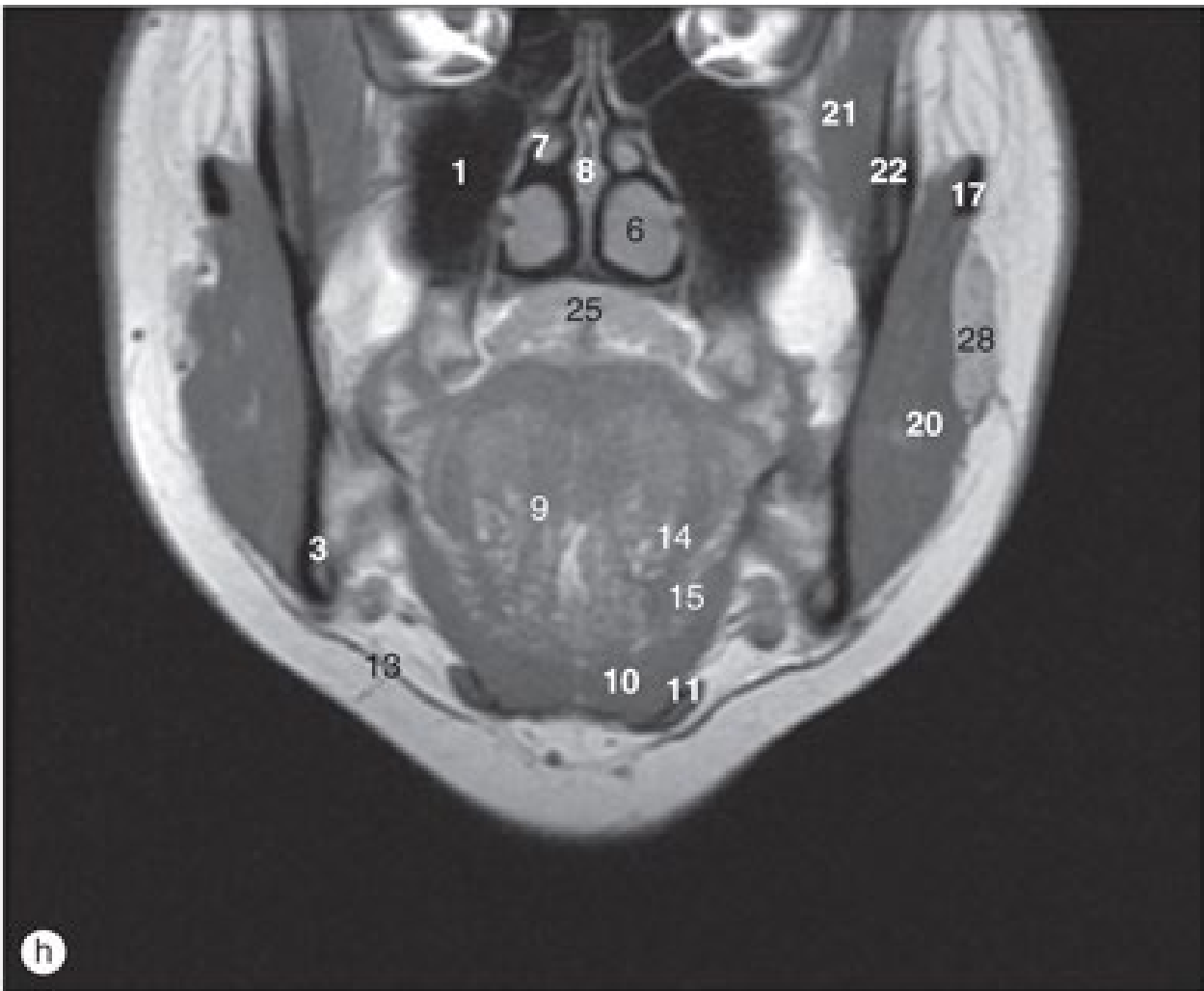
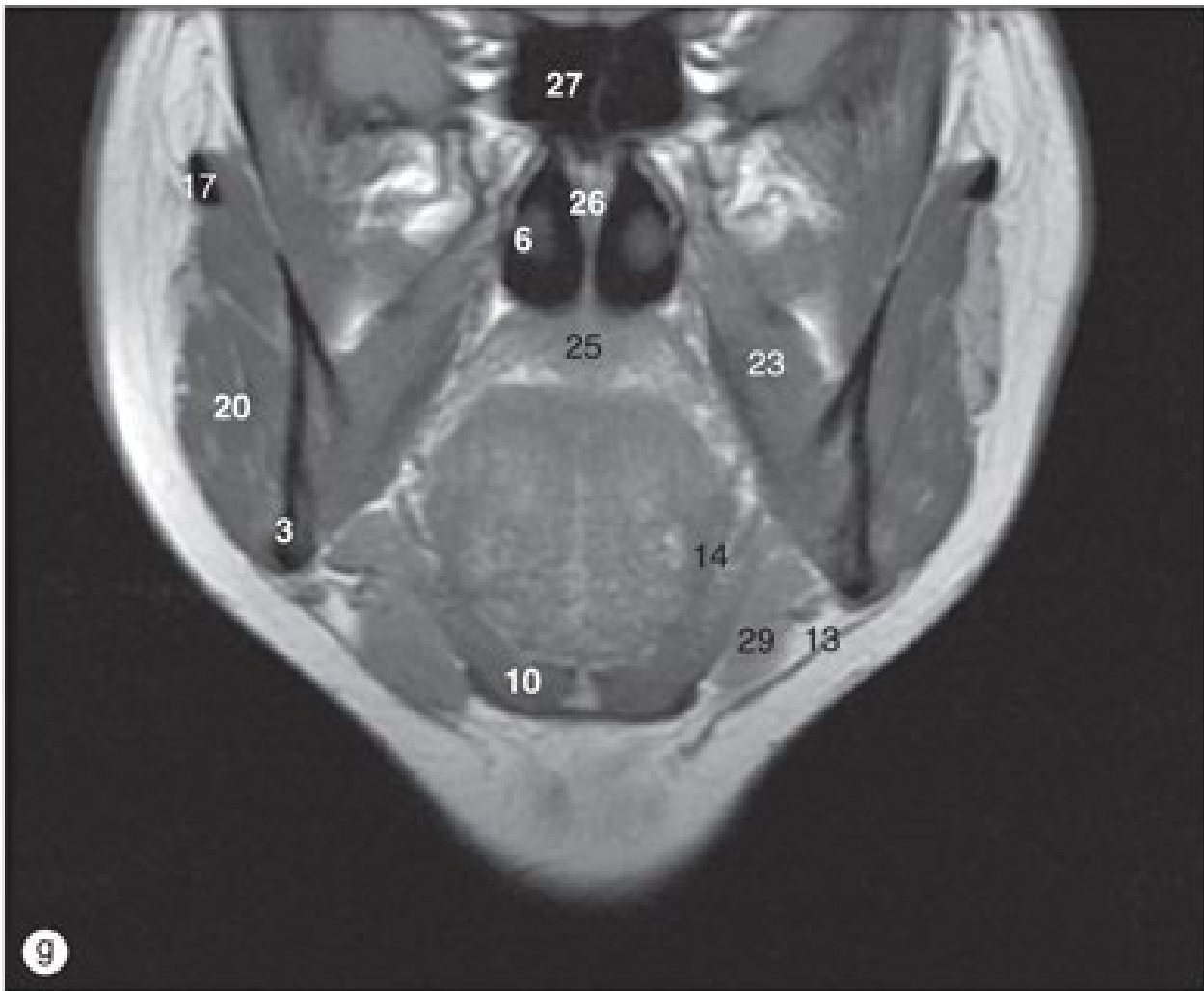
Faringe



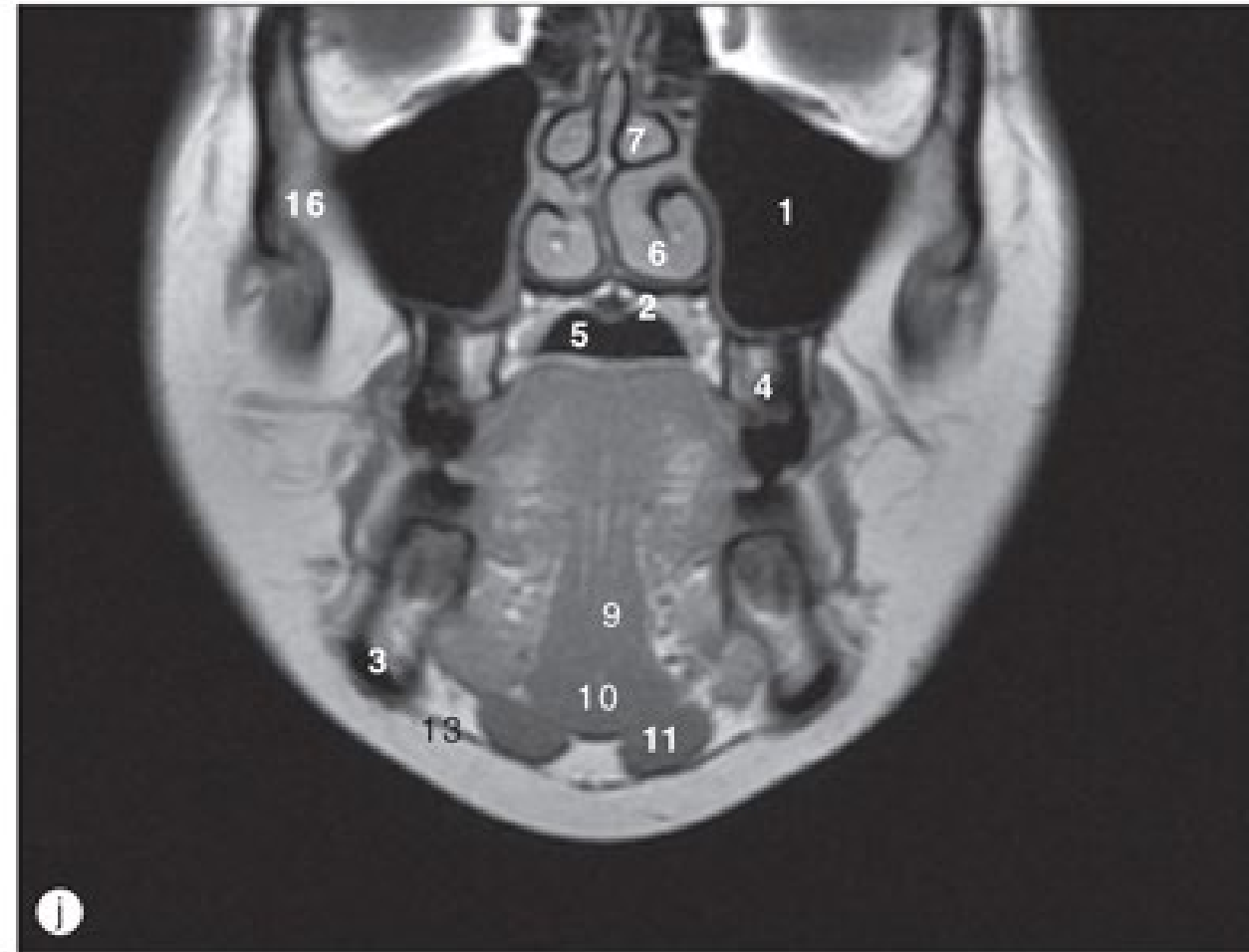
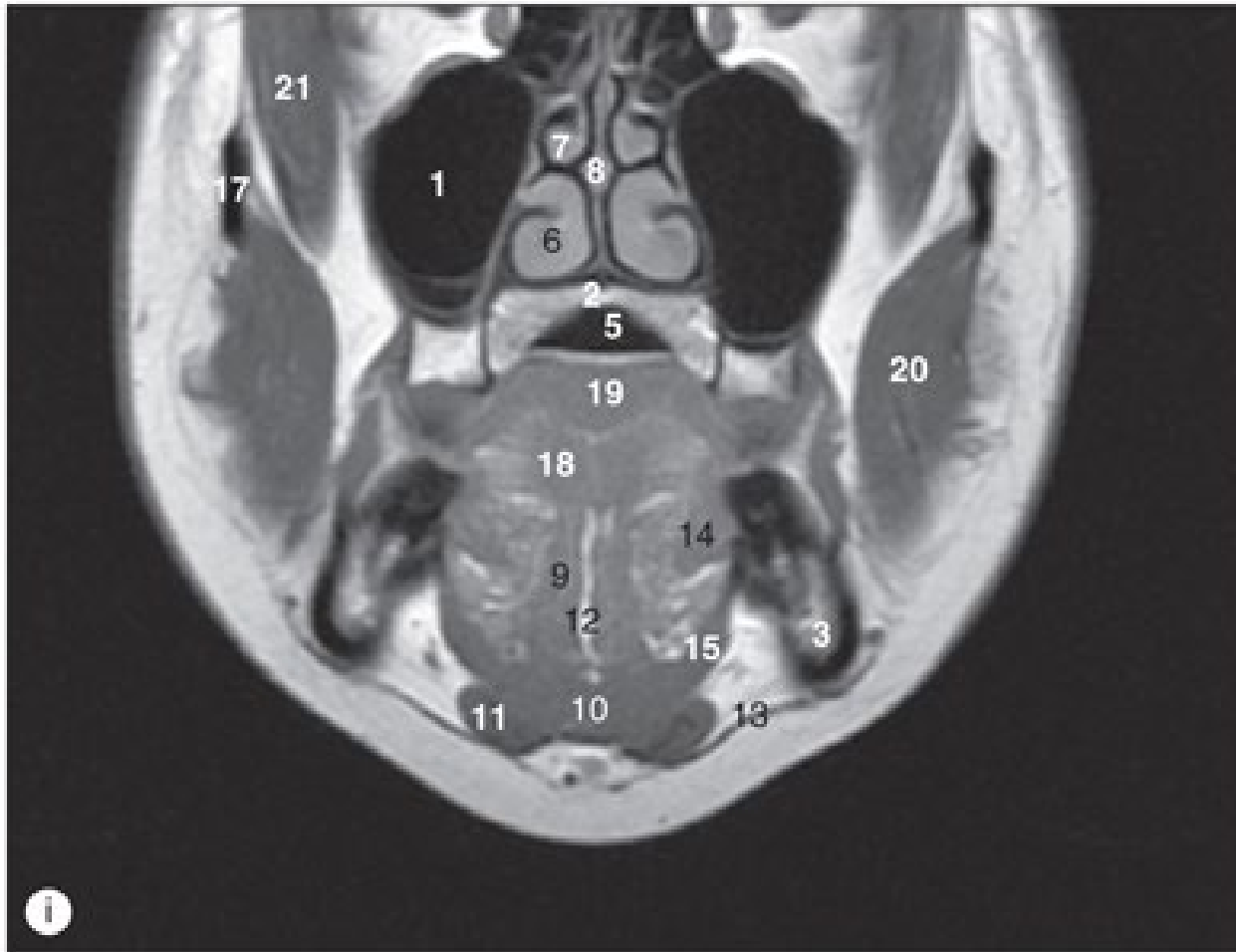
Faringe



Faringe

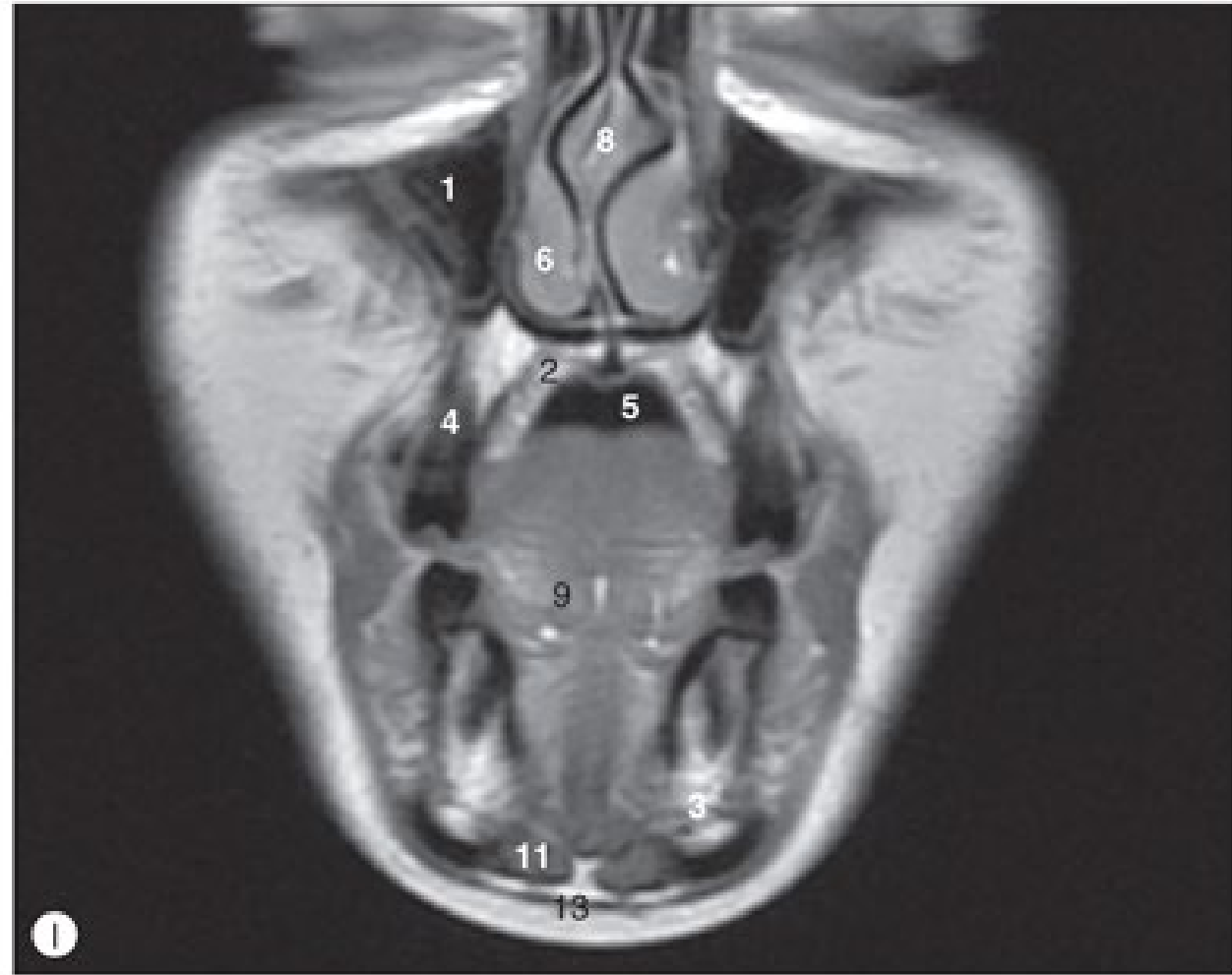
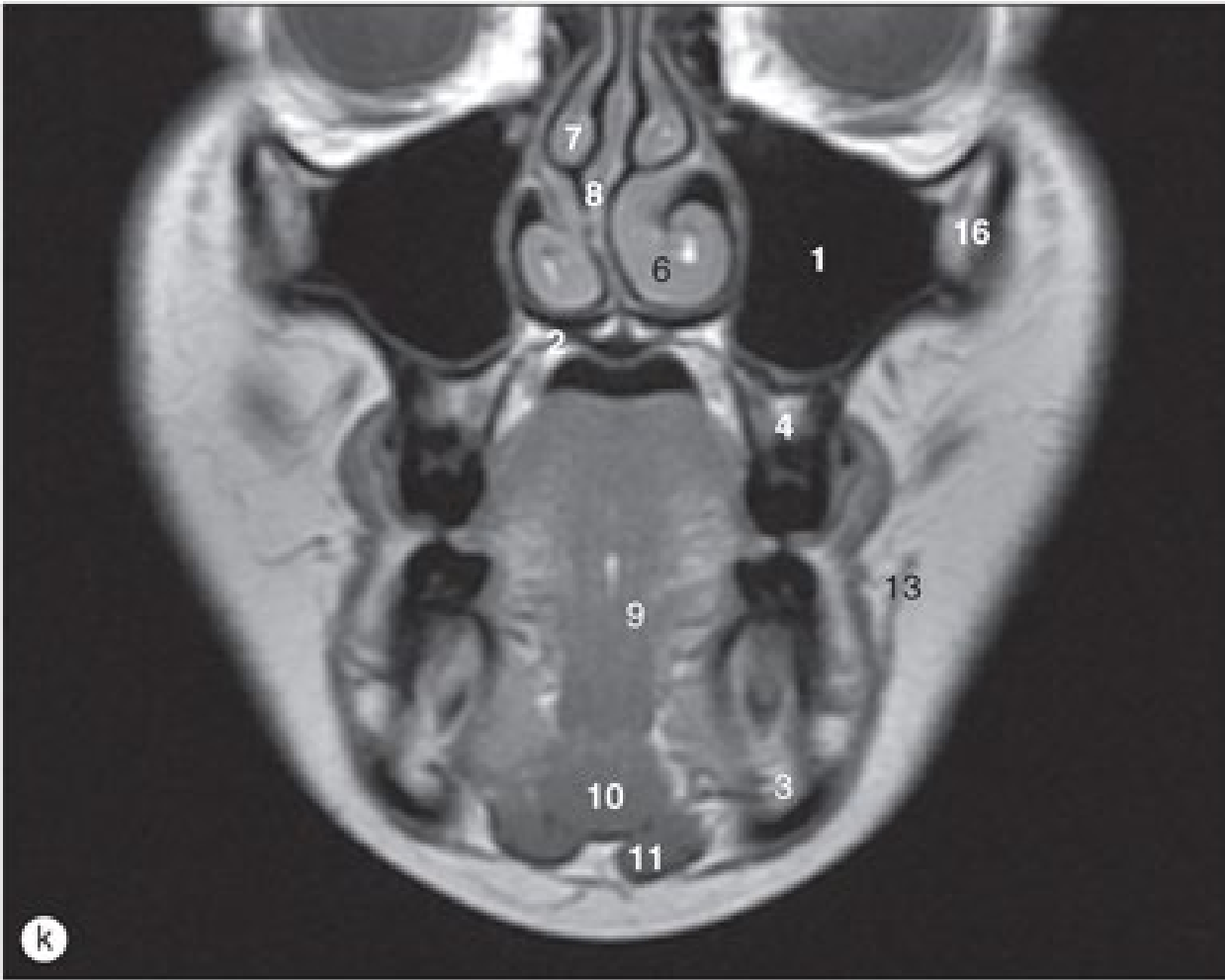


Faringe



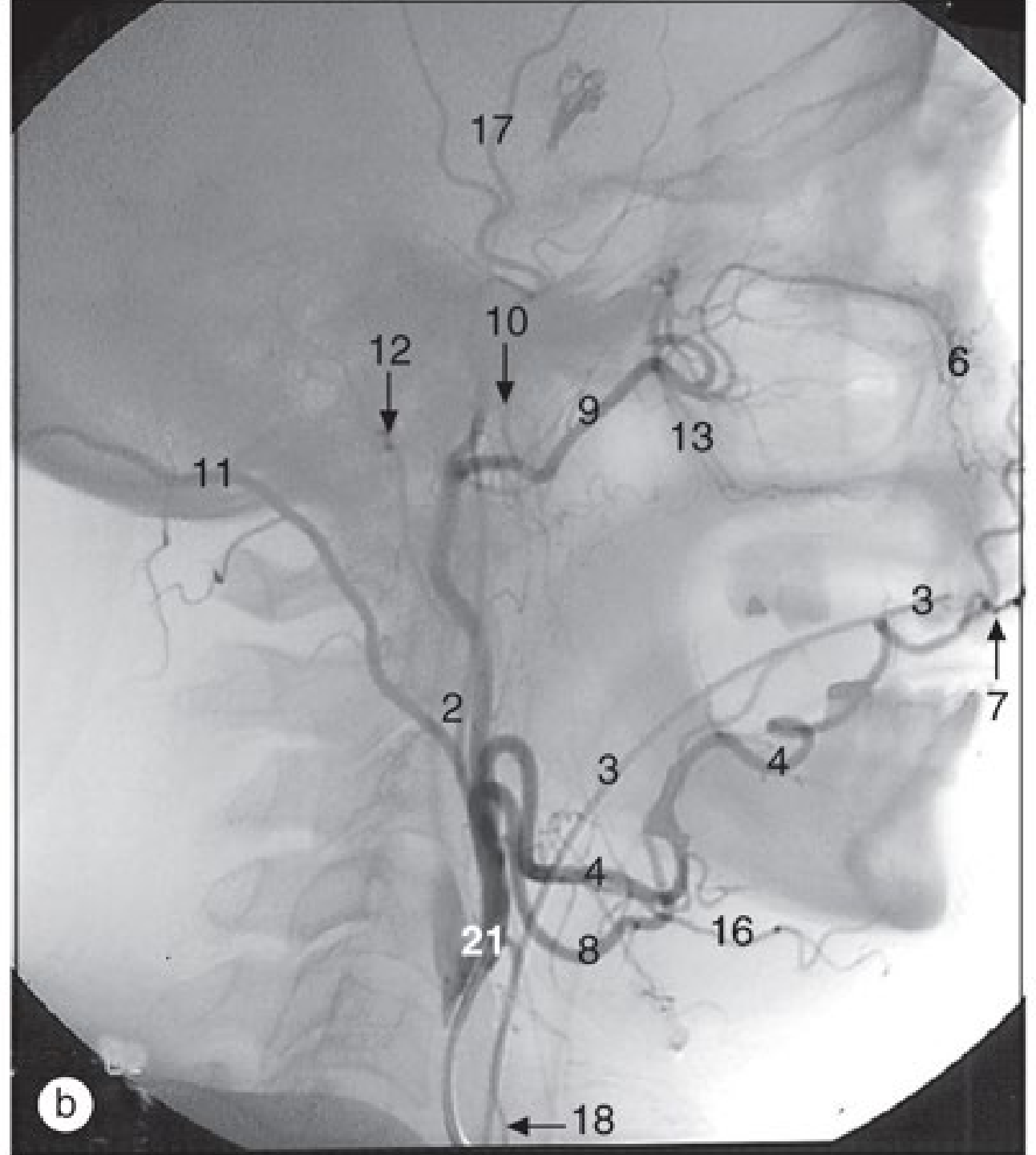
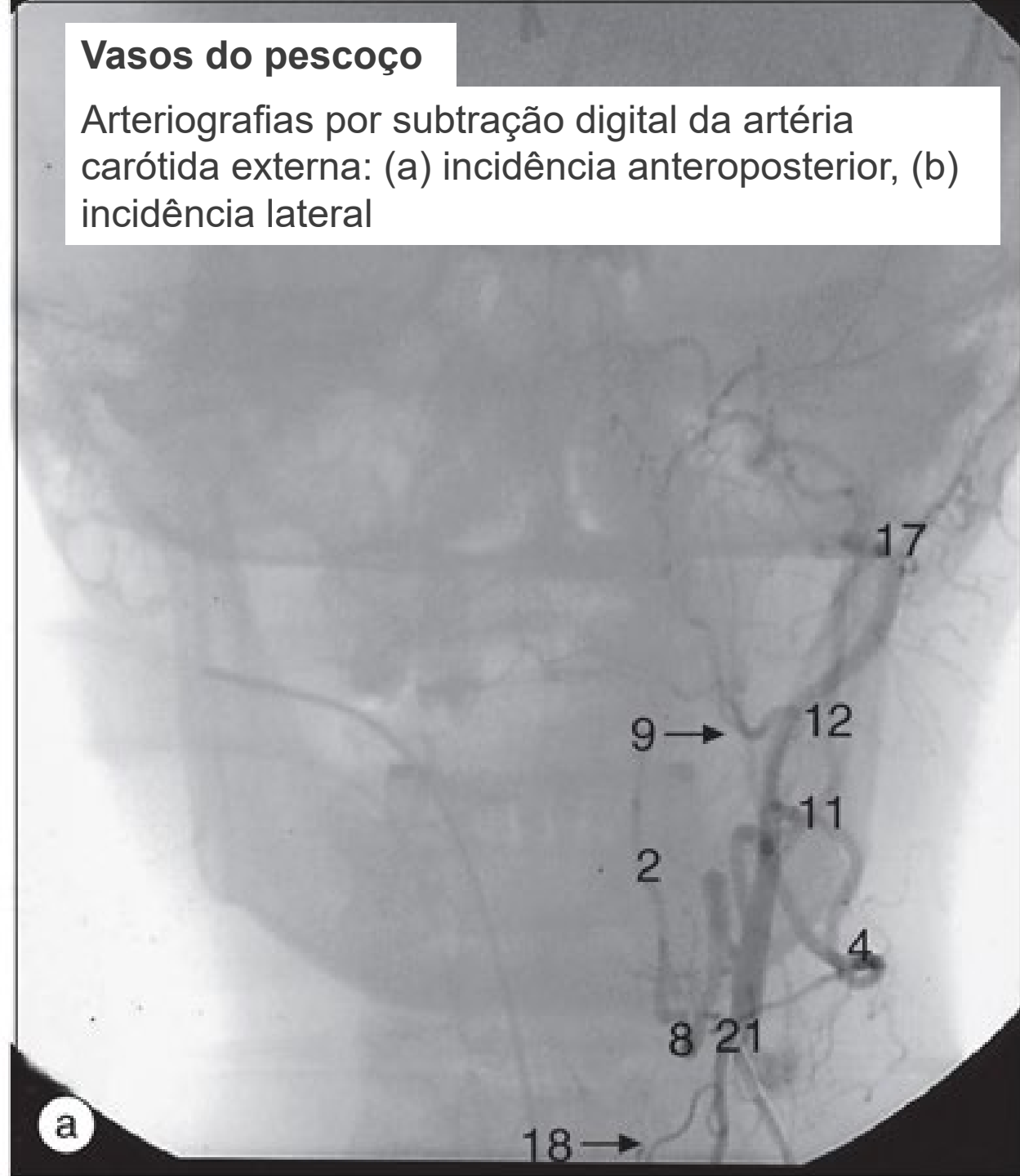
(a)-(I) Faringe, Imagens coronais de RM, de posterior a anterior.

(a)-(l) Faringe, Imagens coronais de RM, de posterior a anterior.



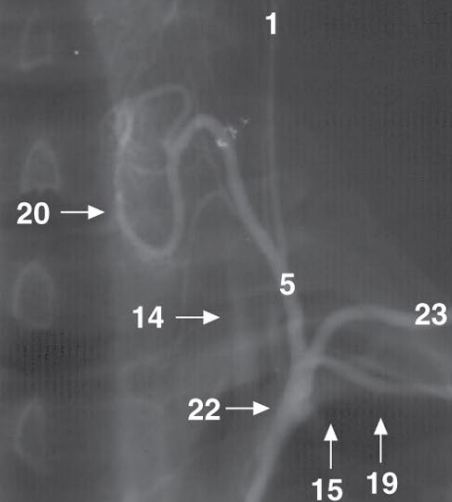
Vasos do pescoço

Arteriografias por subtração digital da artéria carótida externa: (a) incidência anteroposterior, (b) incidência lateral

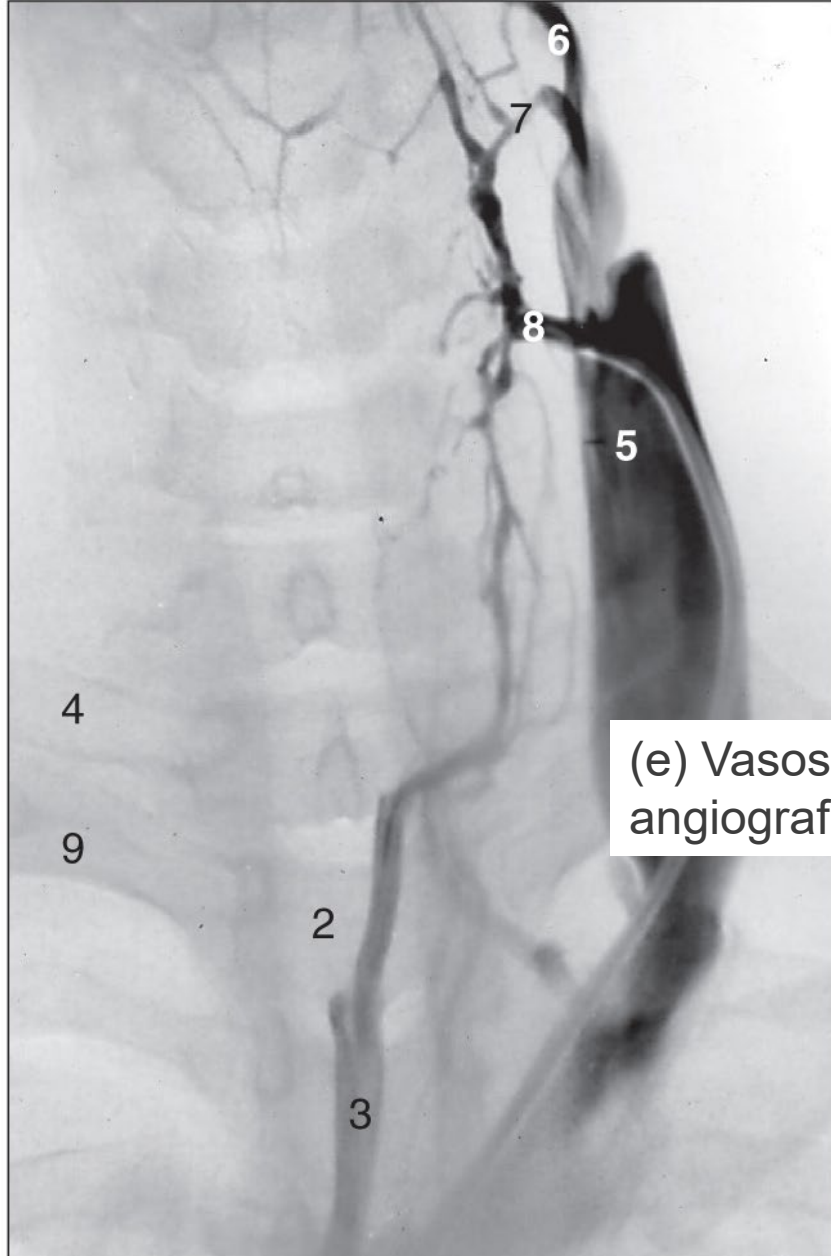


Vasos do pescoço

(c) Arteriografia da tireoide.



c

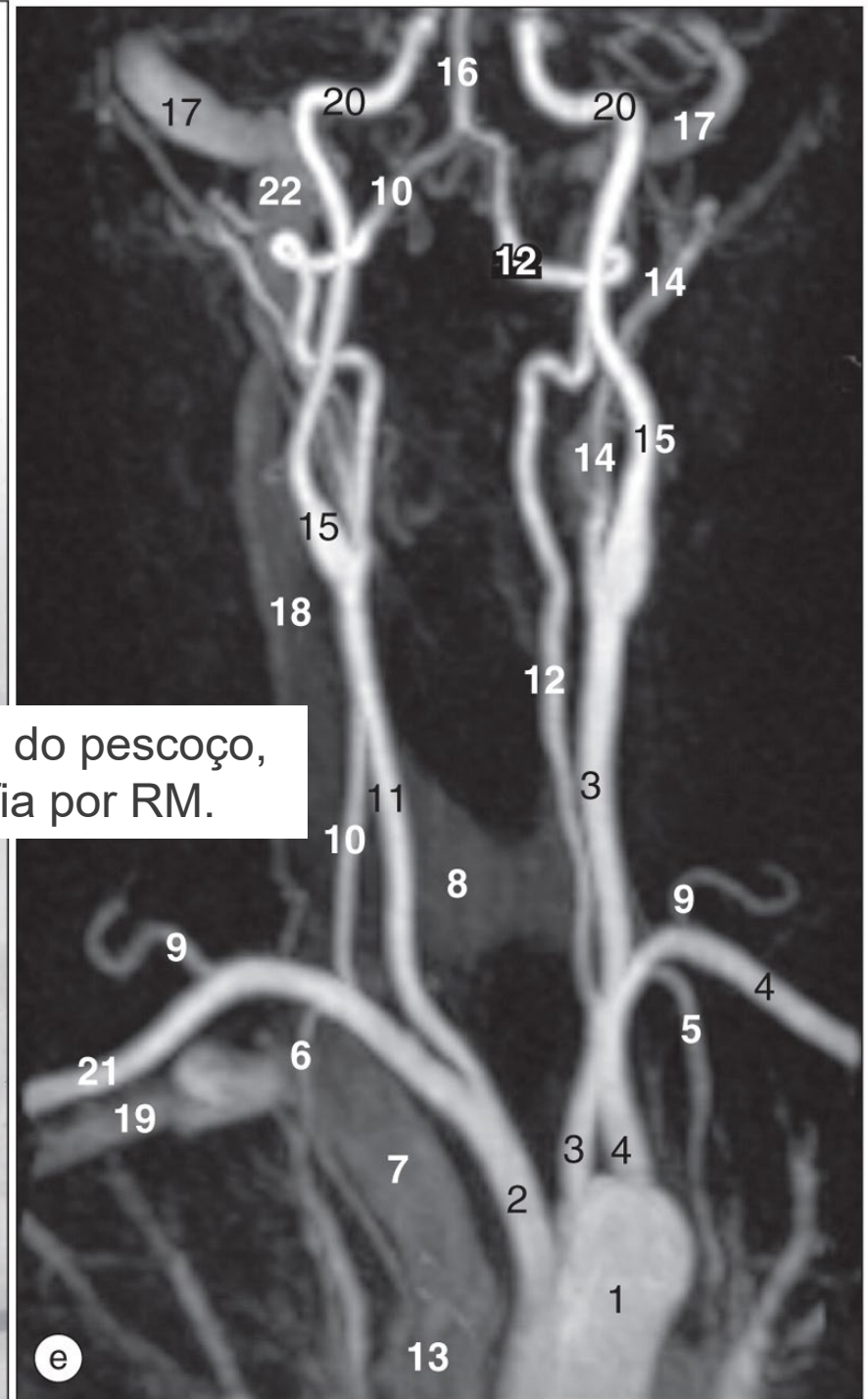


(d) Venografia do pescoço.

d

1

(e) Vasos do pescoço, angiografia por RM.



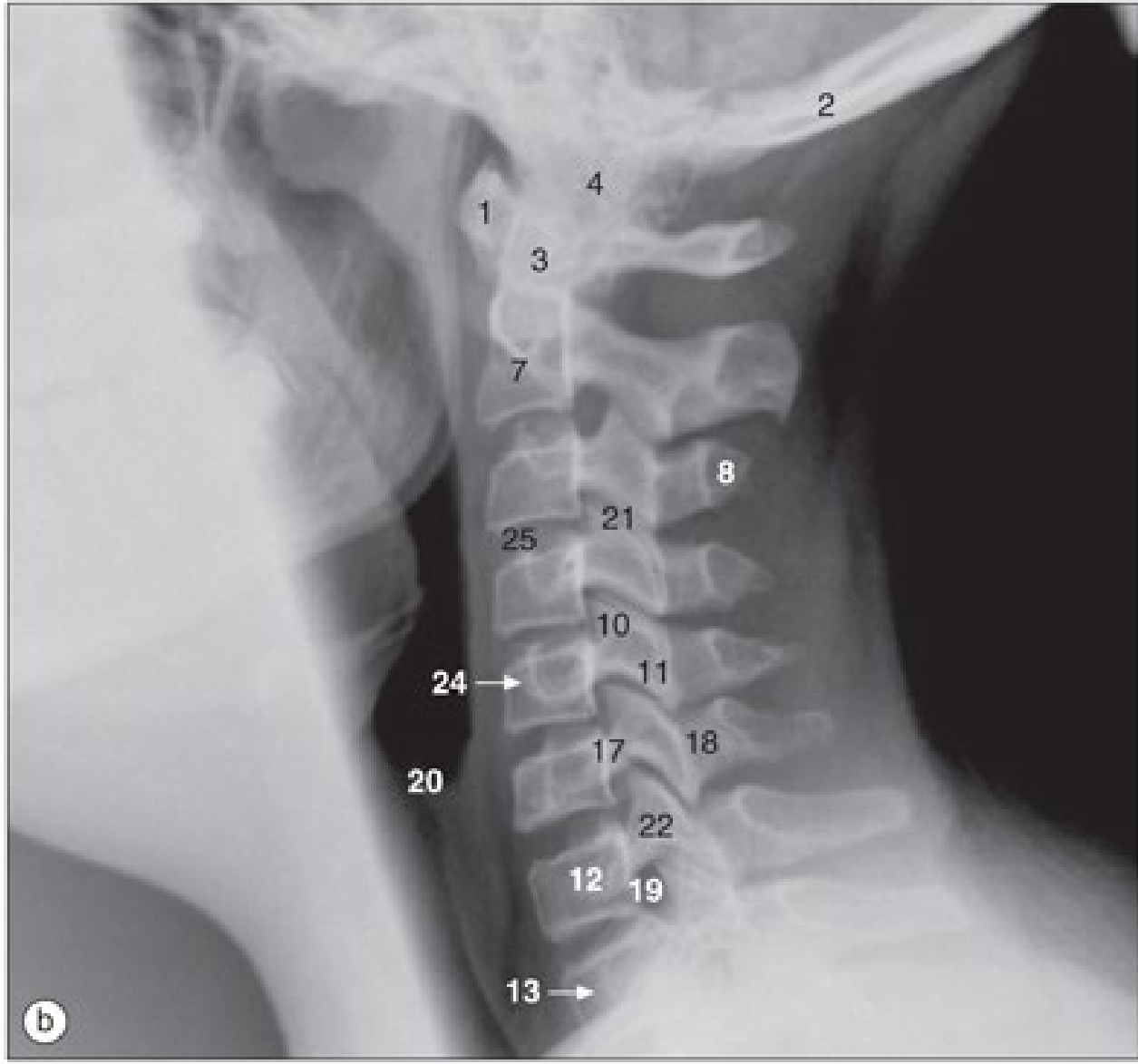
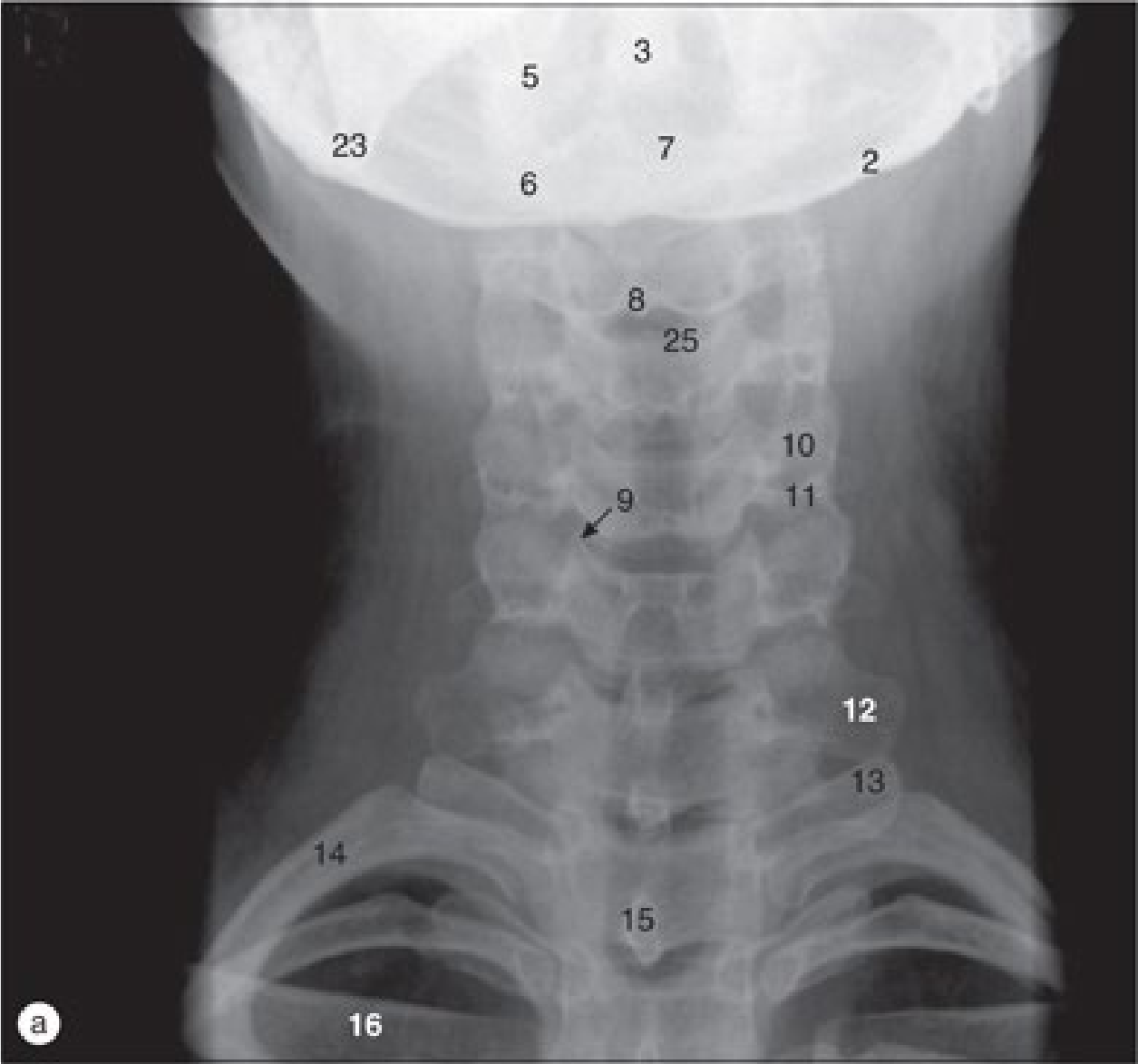
e

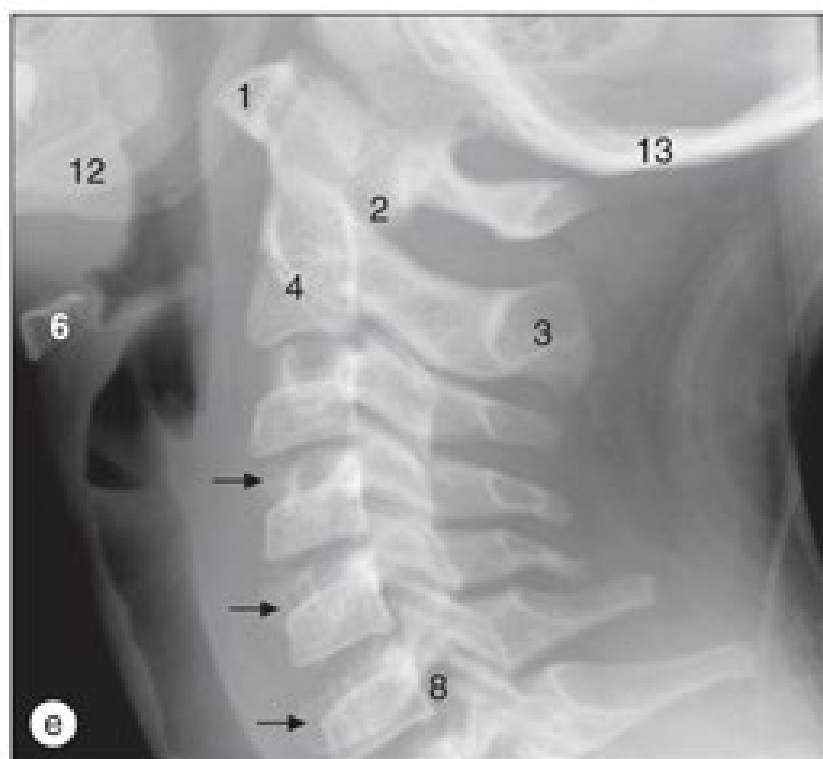
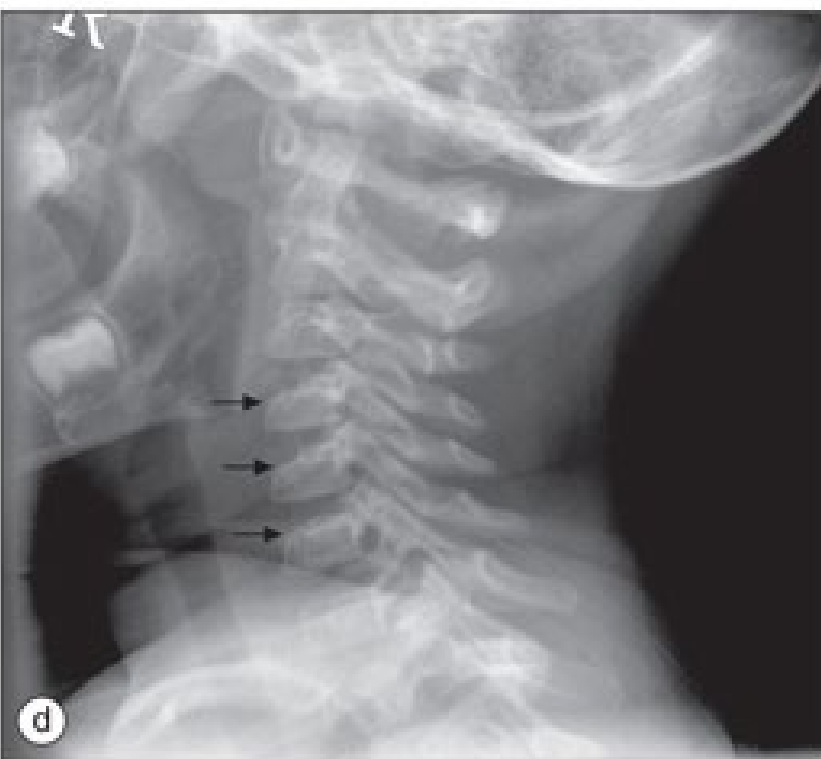
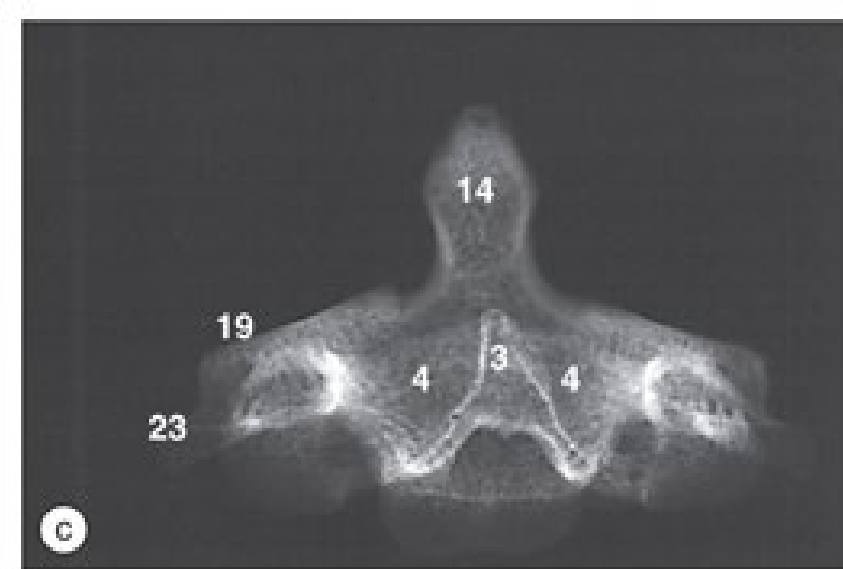
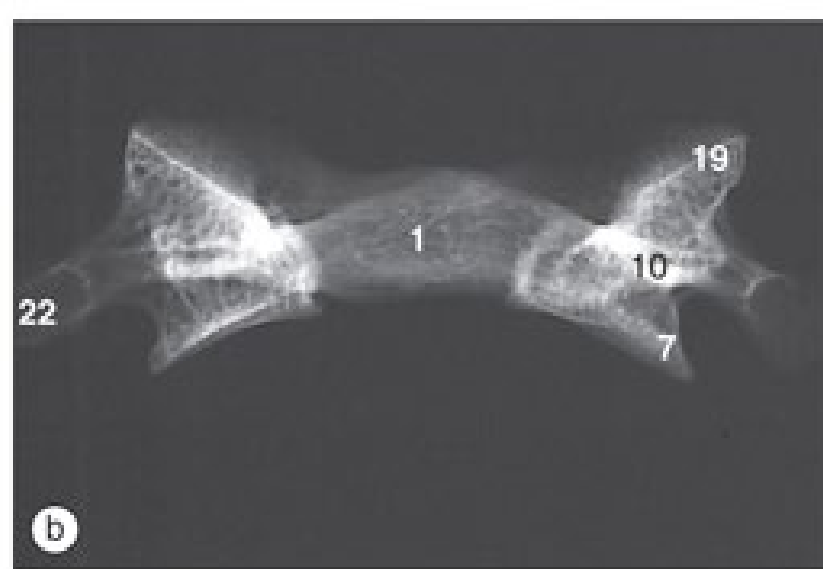
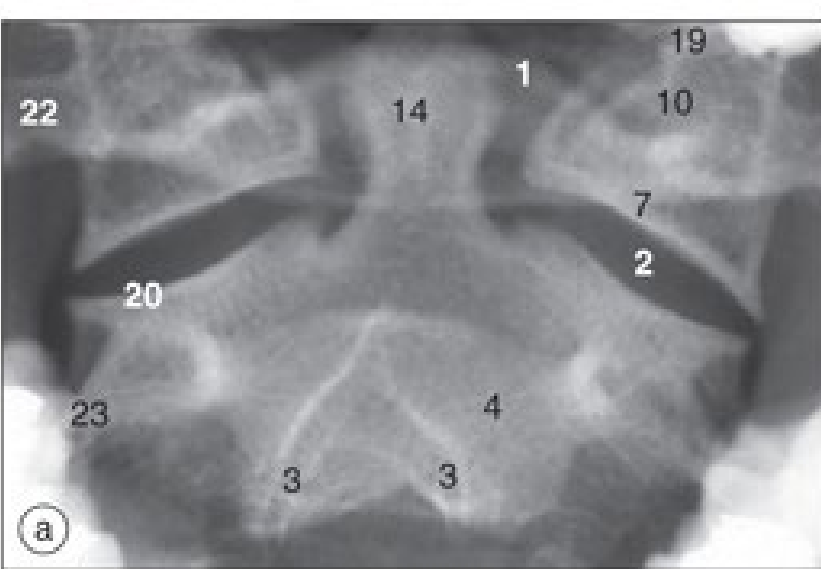
13

Exames de imagens

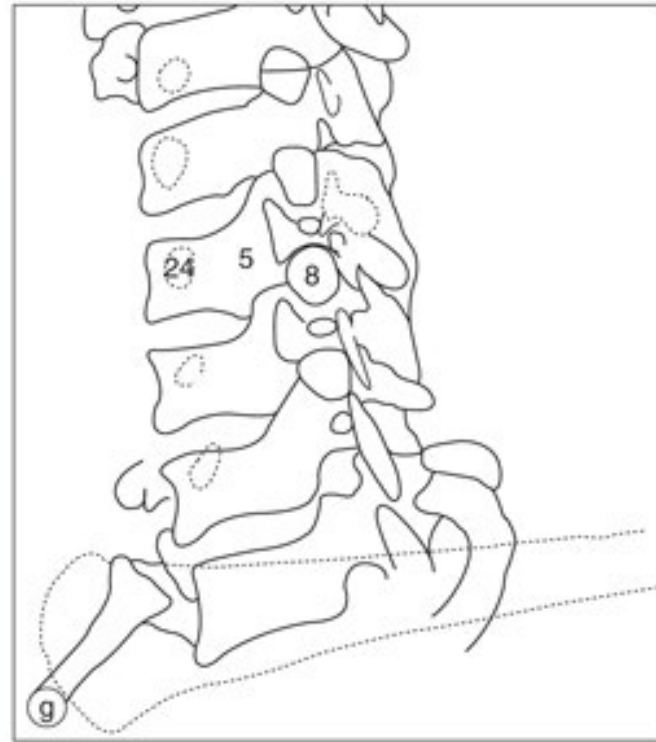
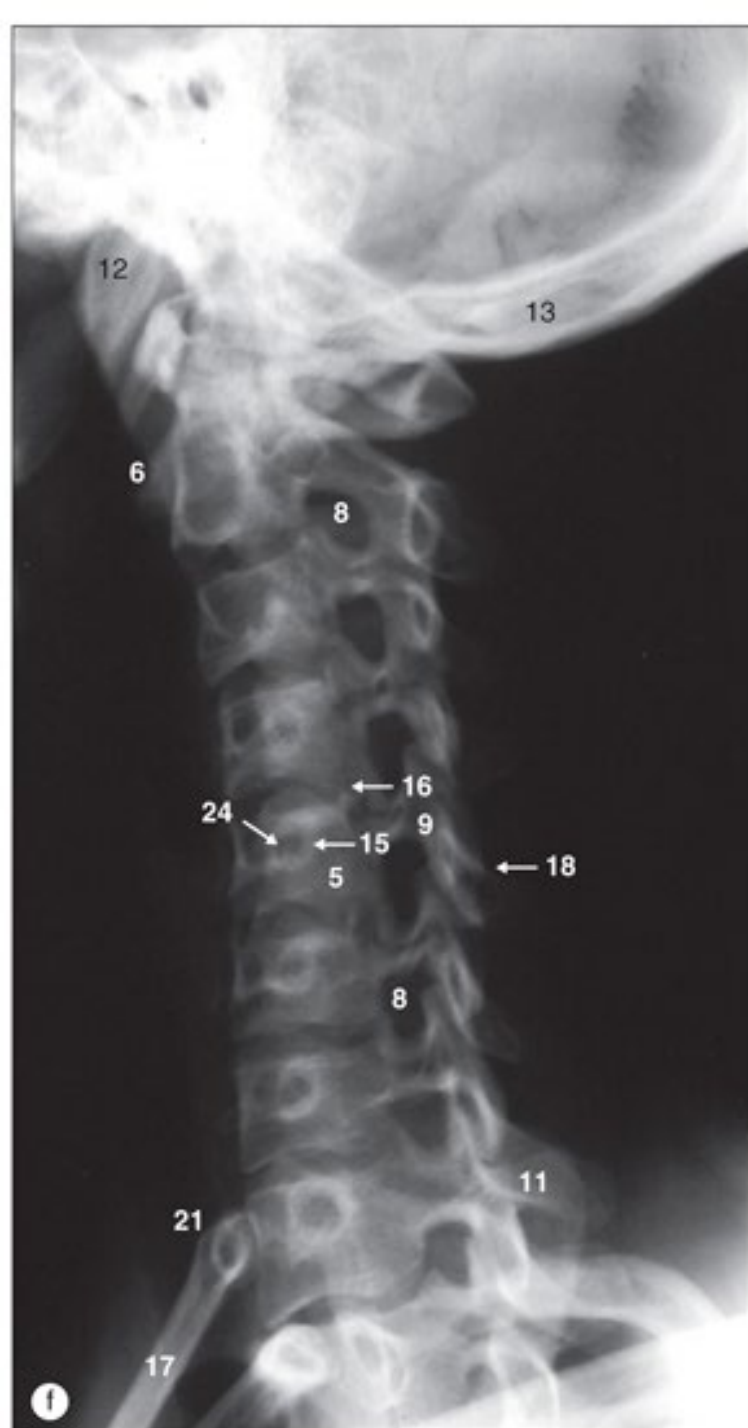
- Encéfalo
- Crânio
- Pescoço
- **Coluna vertebral e medula espinhal**
- Membro superior
- Mama e axila
- Tórax, Pulmões, mediastino
- Vasos do coração
- Abdome
- Pelve
- Ultrassonografia do abdome superior
- Ultrassonografia de abdome e pelve
- Quadril
- Membros inferiores
- Exames funcionais

Coluna vertebral e medula espinal

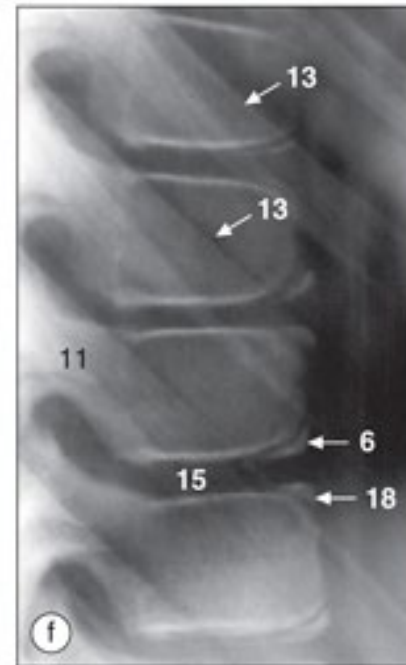
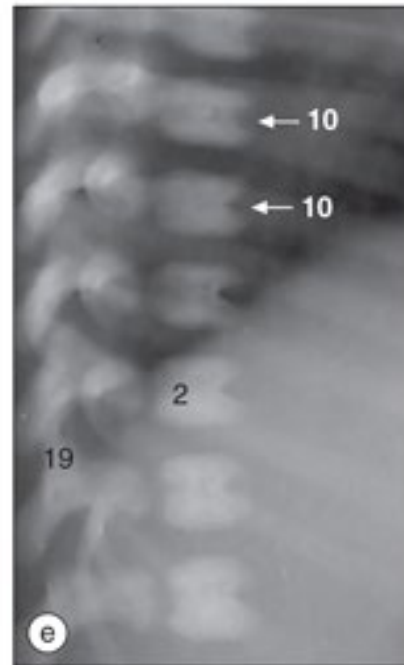
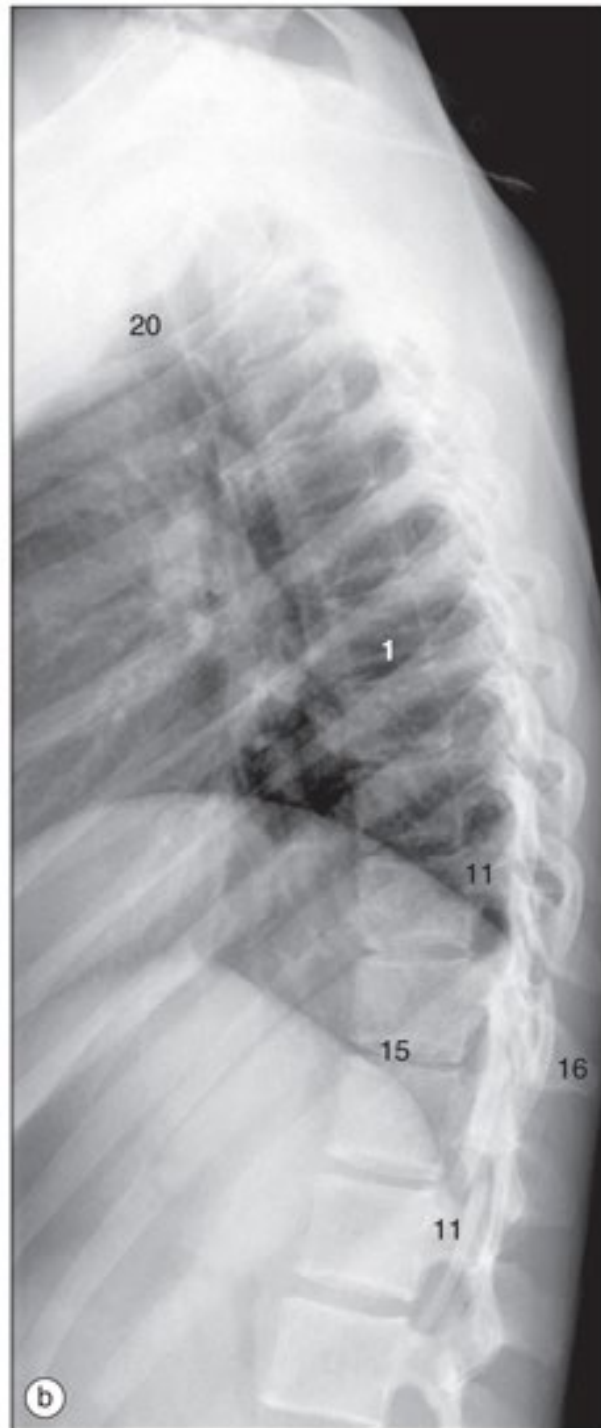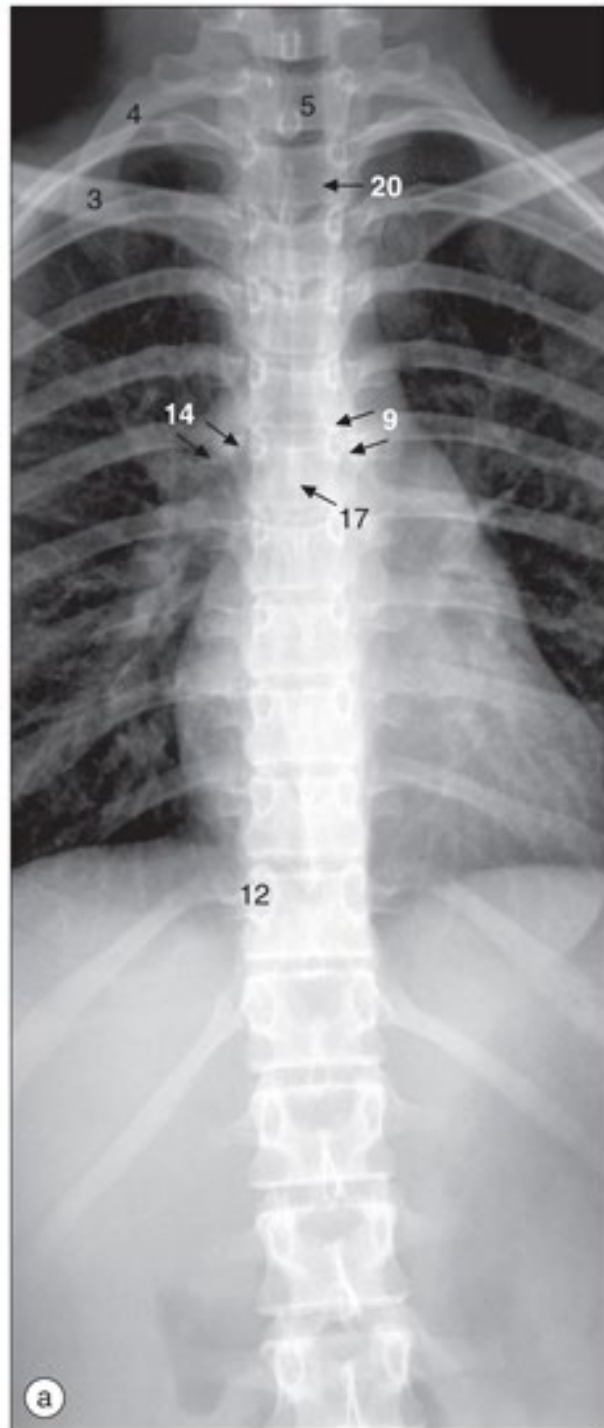




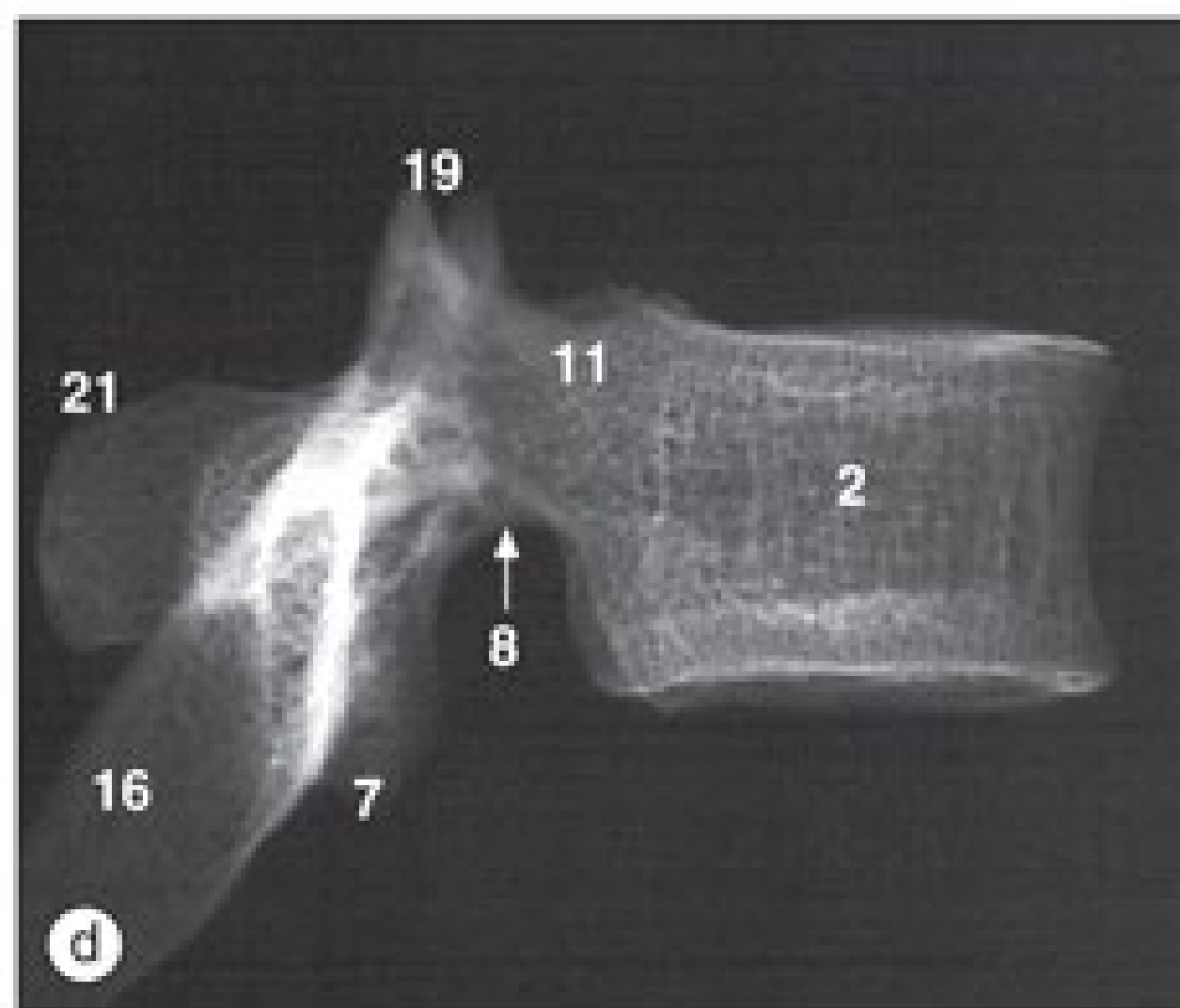
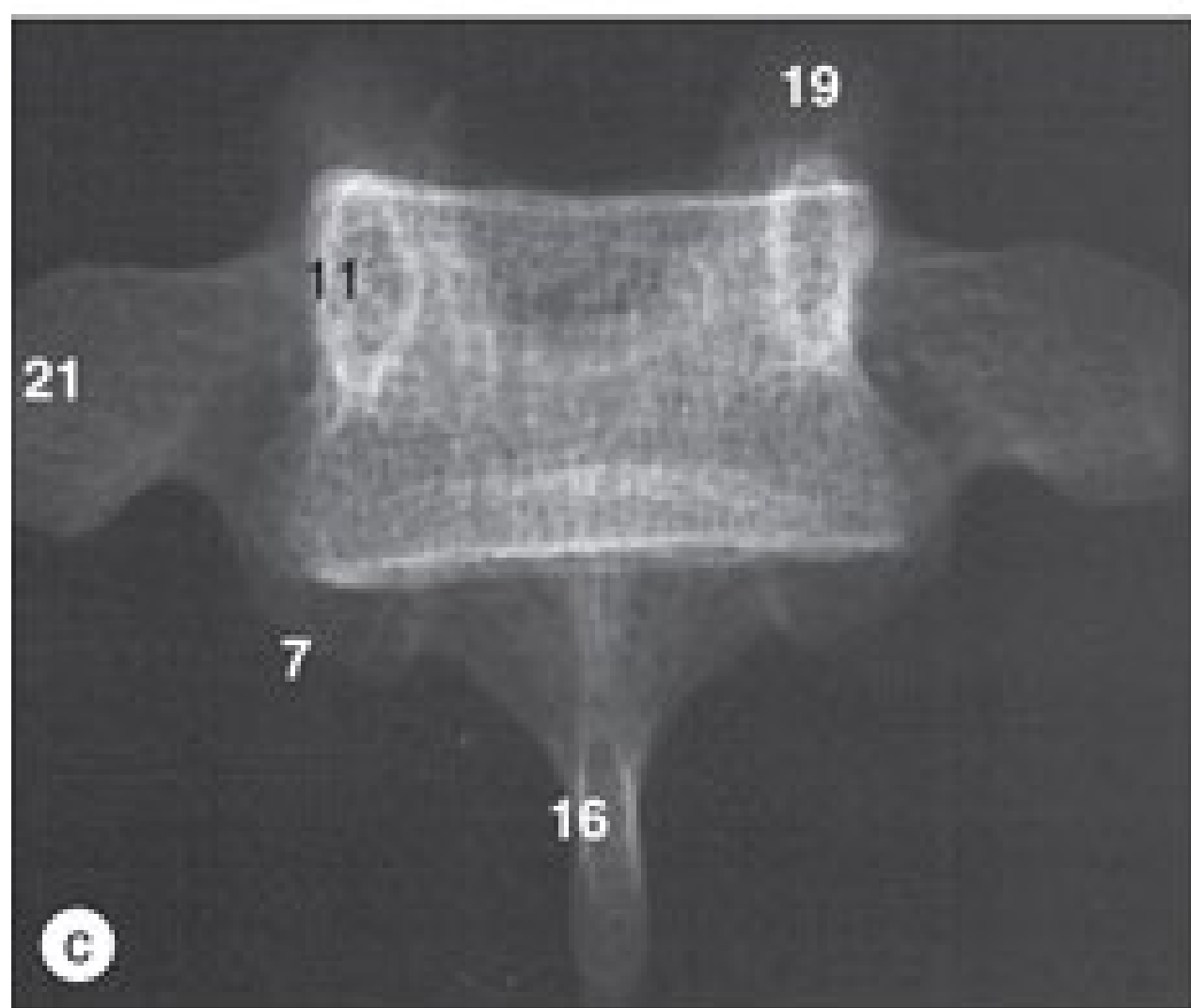
a) Atlas (primeira vértebra cervical) e áxis (segunda vértebra cervical), radiografia anteroposterior com a “boca aberta”. (b) Atlas dessecado (primeira vértebra cervical), radiografia anteroposterior. (c) Áxis dessecado (segunda vértebra cervical), radiografia anteroposterior. (d) Radiografia lateral da coluna cervical de uma criança de três anos. A articulação atlantoaxial normalmente pode ter até 5 mm (até 3 mm em adultos). (e) Radiografia lateral da coluna cervical de uma criança de nove anos. Note o acunhamento normal dos corpos vertebrais (setas) devido à ausência de ossificação da placa terminal superior dos corpos vertebrais.



(f) Radiografia oblíqua da coluna cervical de um adulto.
(g) Desenho de (f).

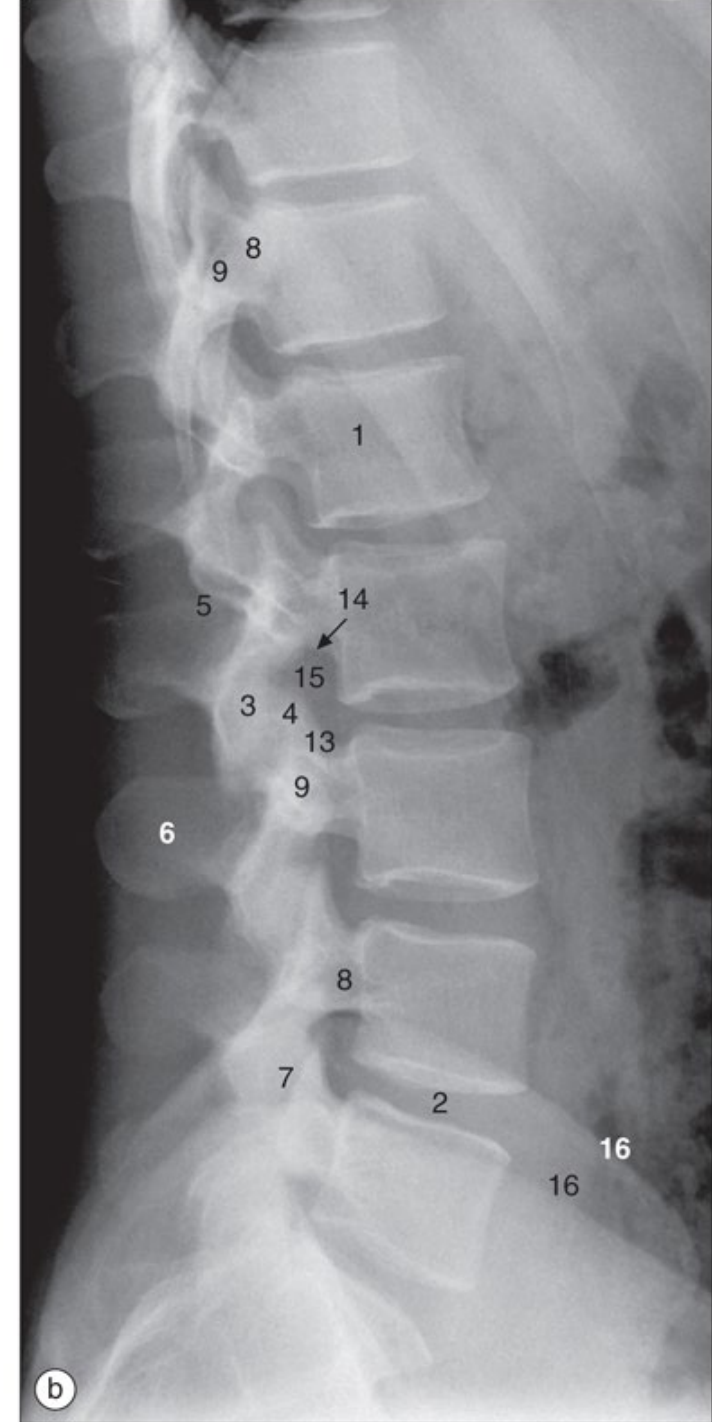
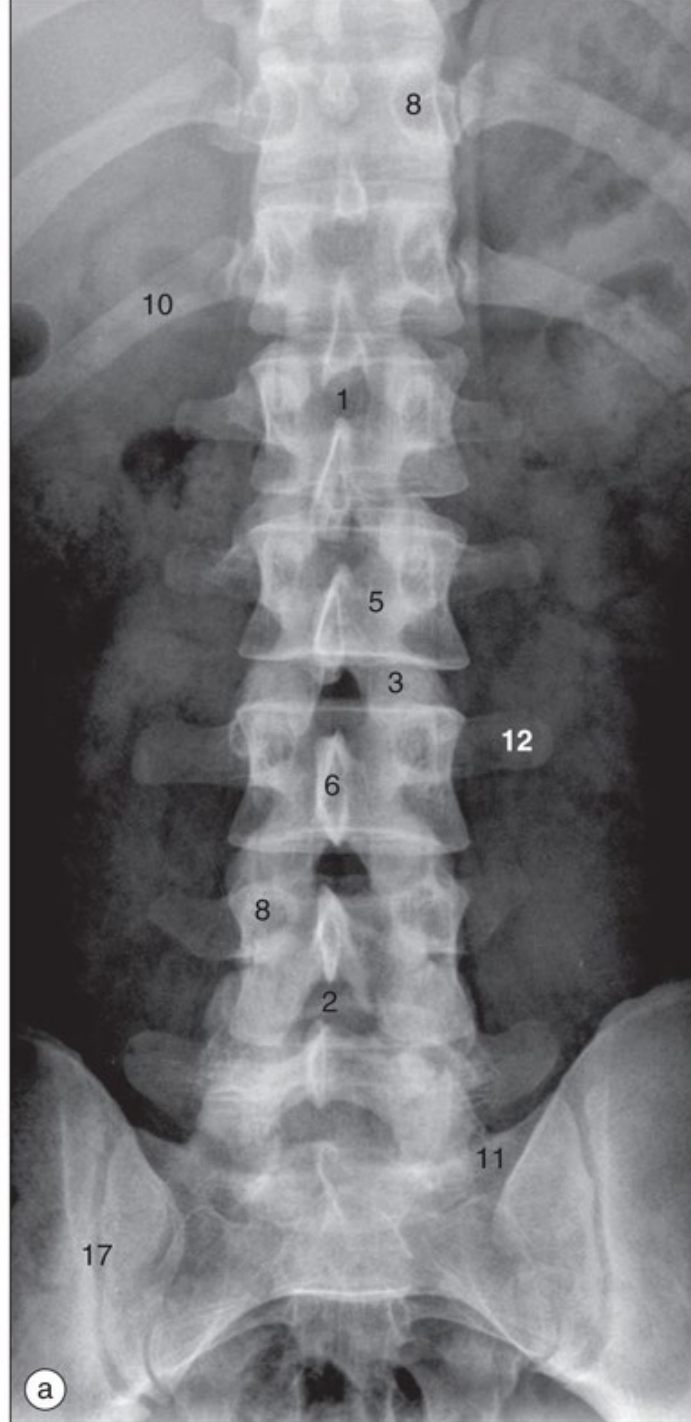


(a) Coluna torácica, radiografia anteroposterior. (b) Coluna torácica, radiografia lateral.

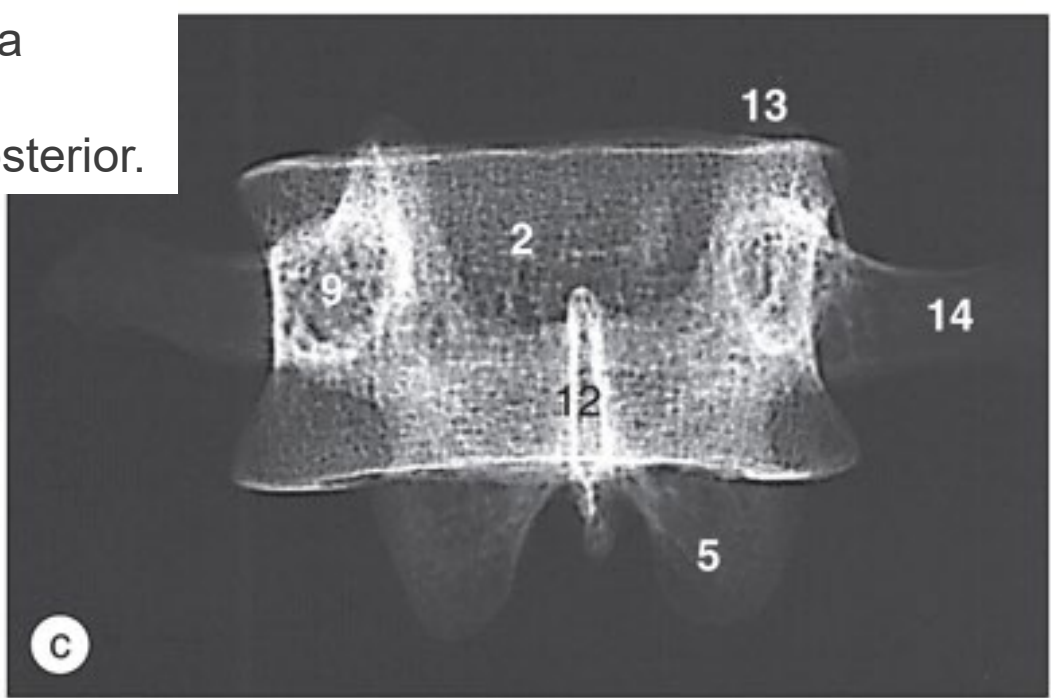


c) Vértebra torácica (peça seca), radiografia anteroposterior. (d) Sexta vértebra torácica (peça seca), radiografia lateral. Coluna torácica,

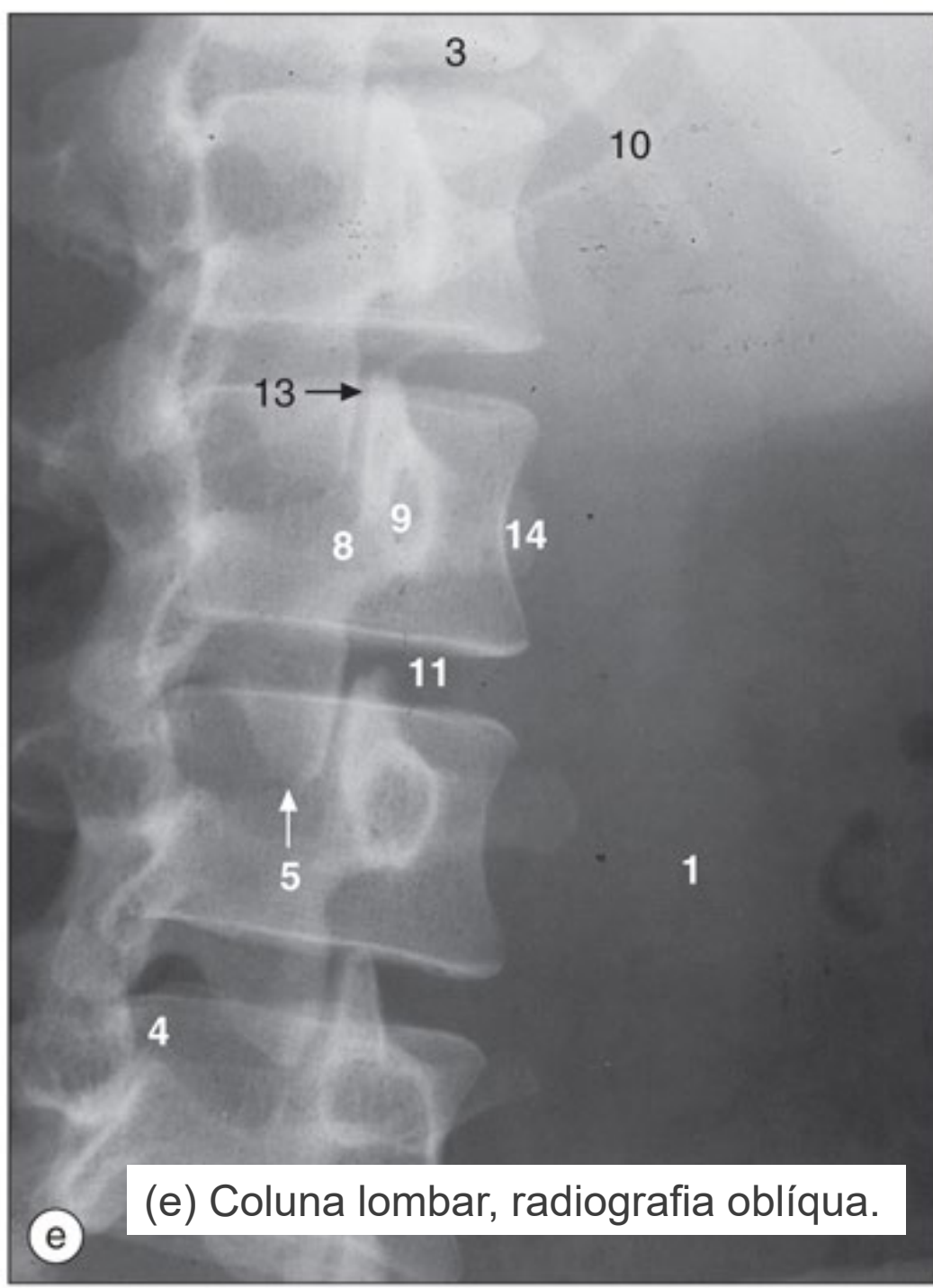
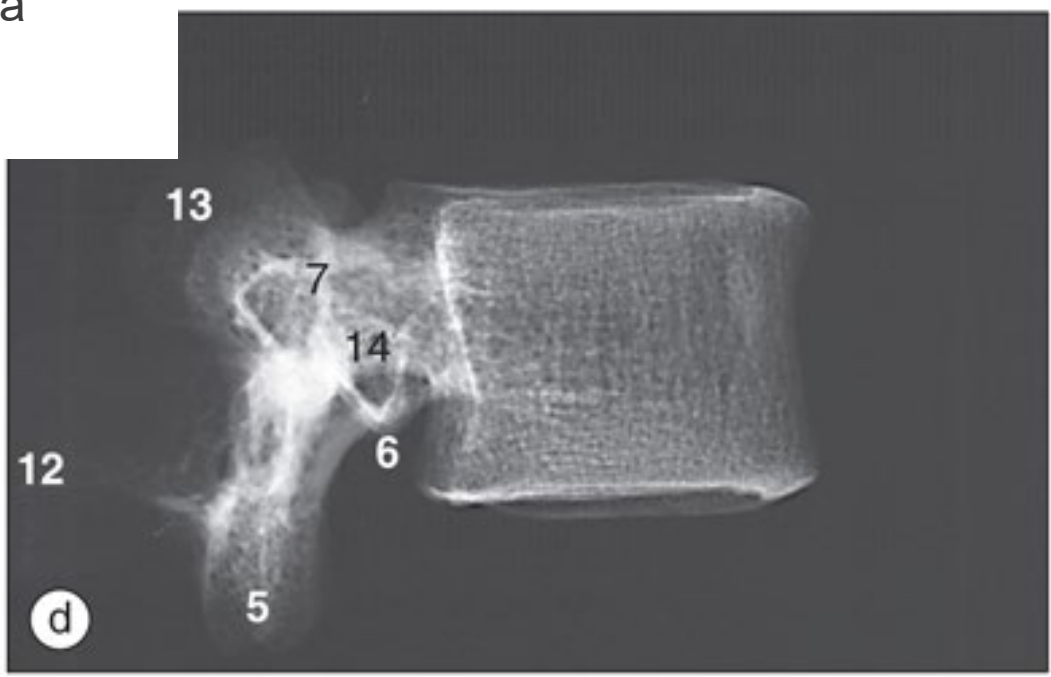
(a) Coluna lombar, radiografia anteroposterior. (b)
Coluna lombar, radiografia lateral.



(c) Segunda vértebra lombar dessecada, radiografia anteroposterior.

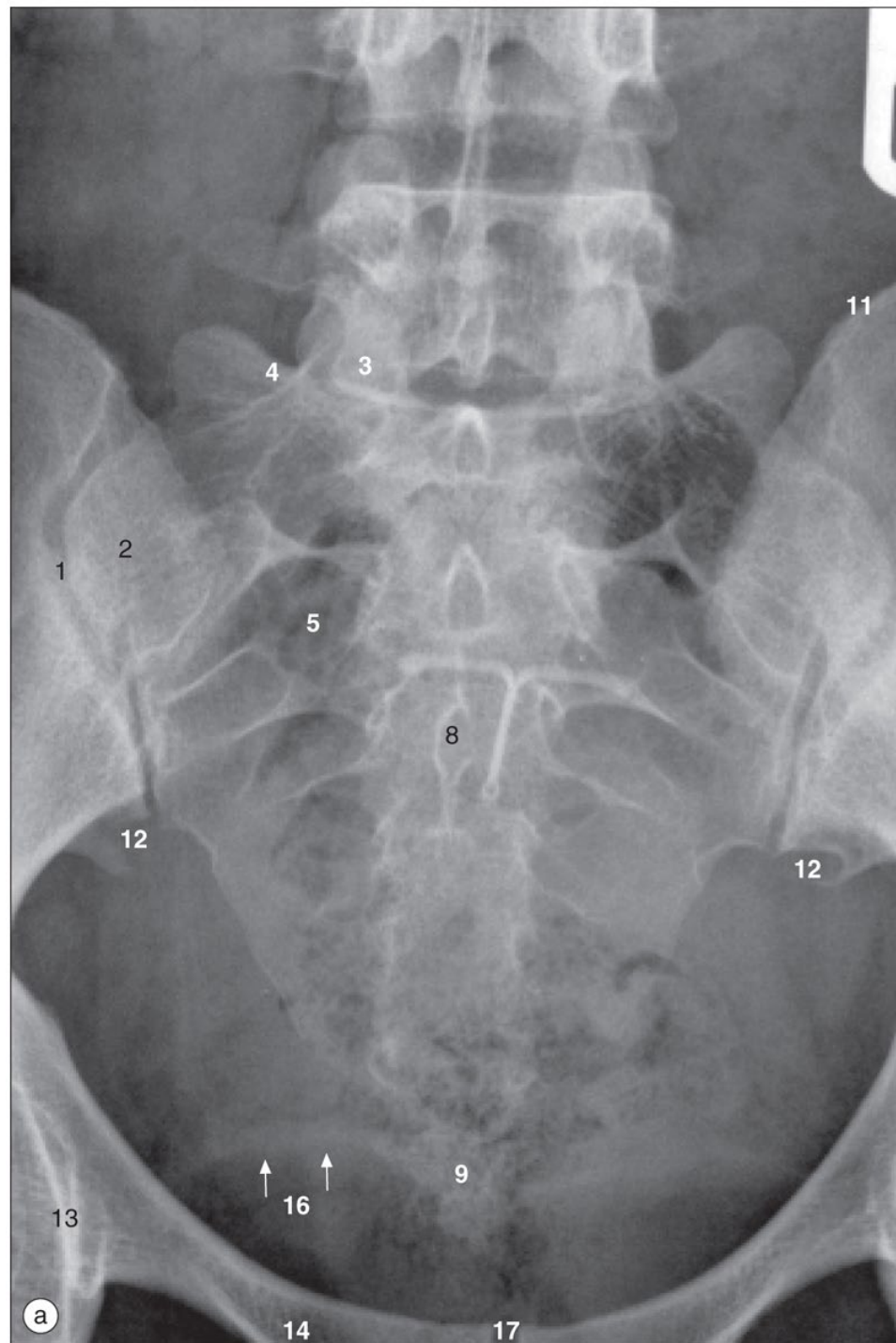


(d) Segunda vértebra lombar dessecada, radiografia lateral.

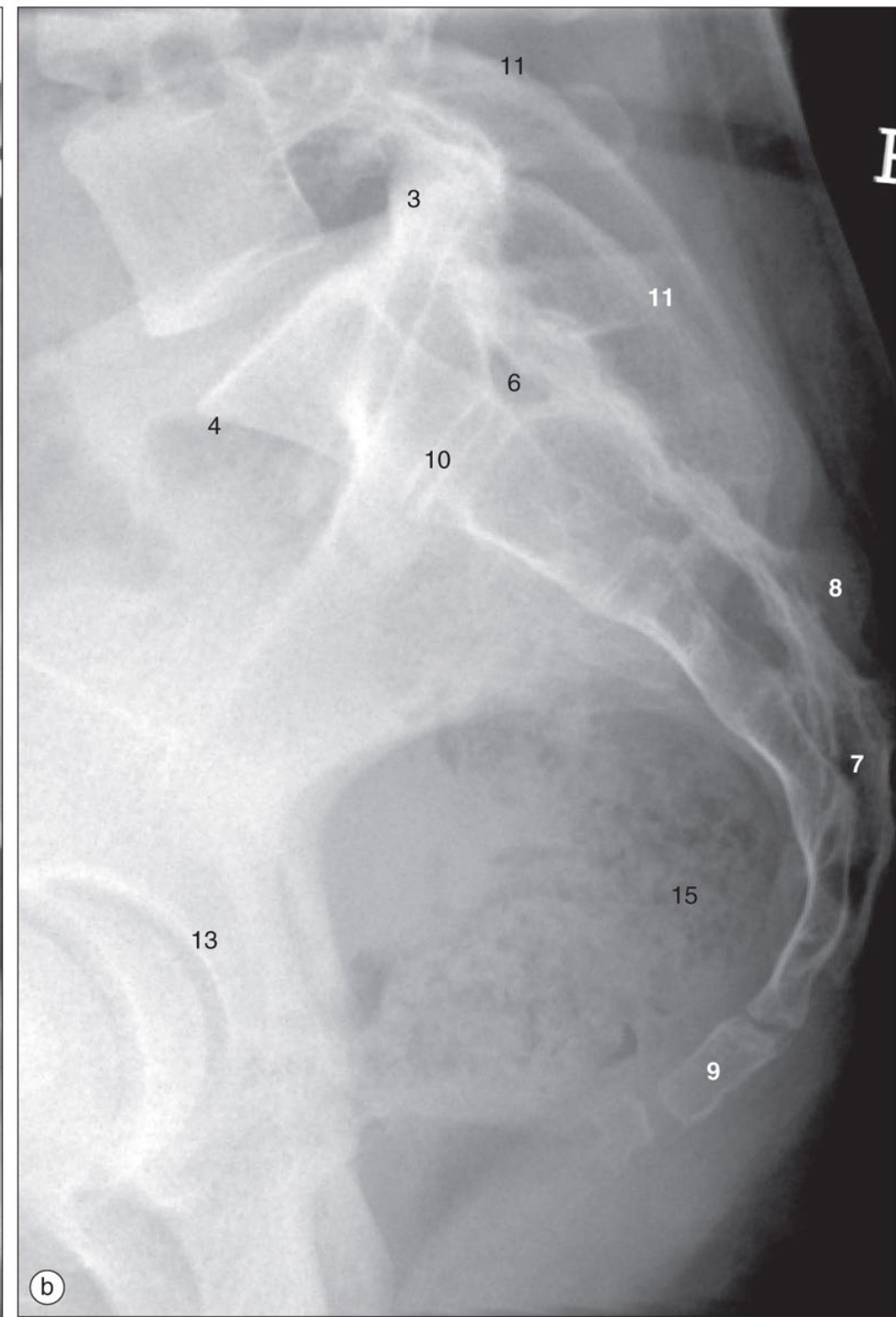


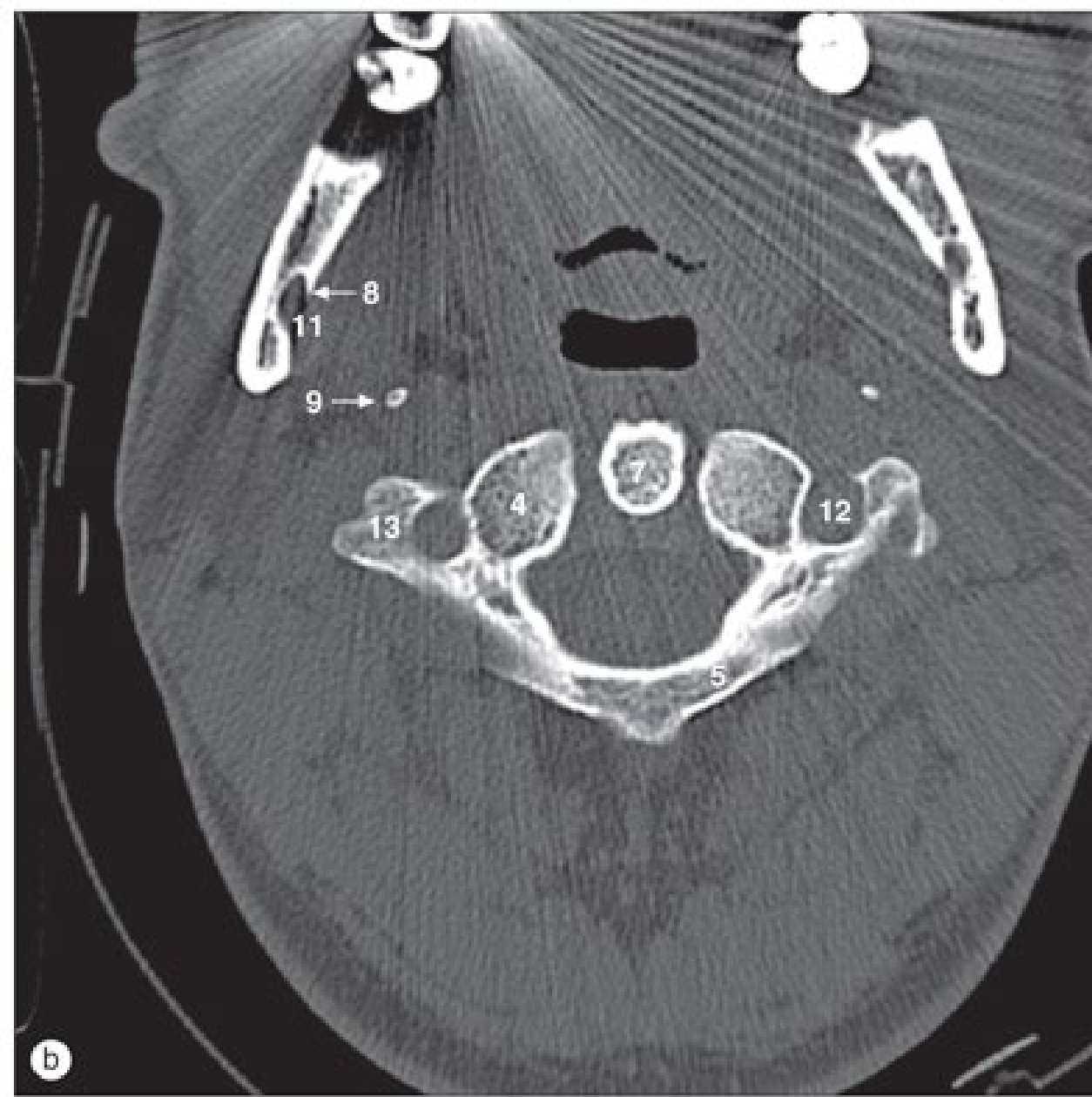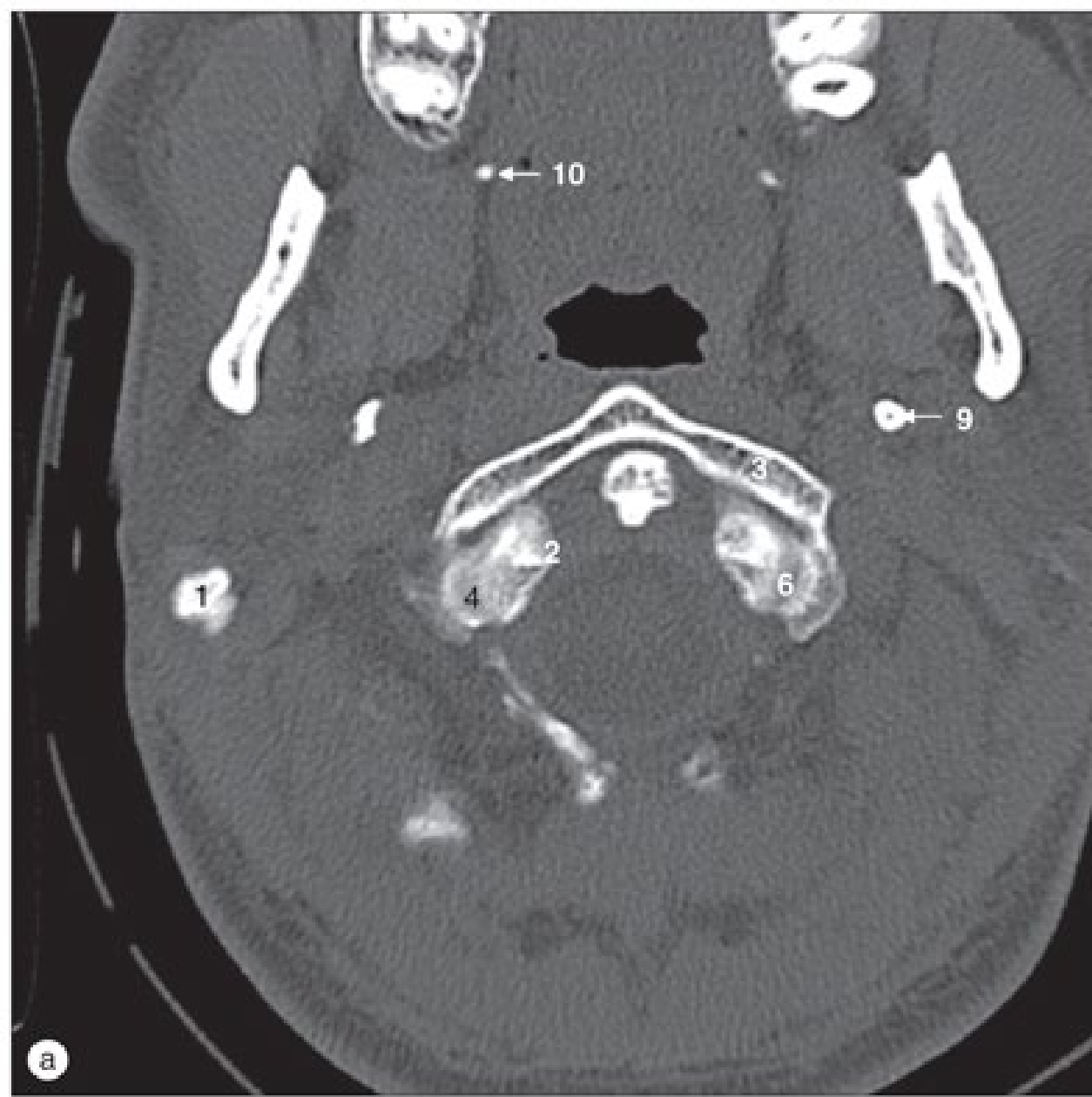
(e) Coluna lombar, radiografia oblíqua.

(a) Sacro, radiografia anteroposterior.

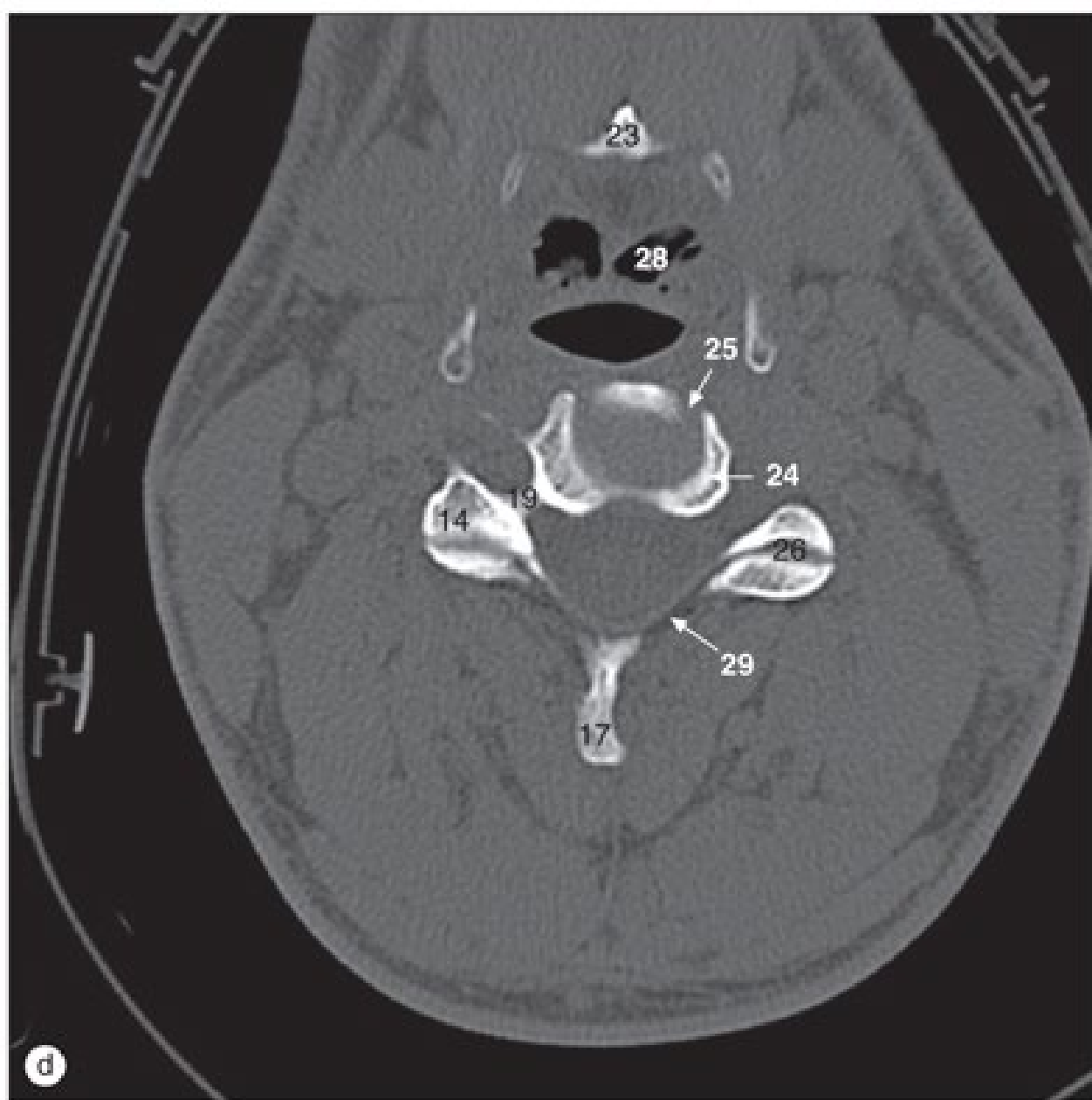
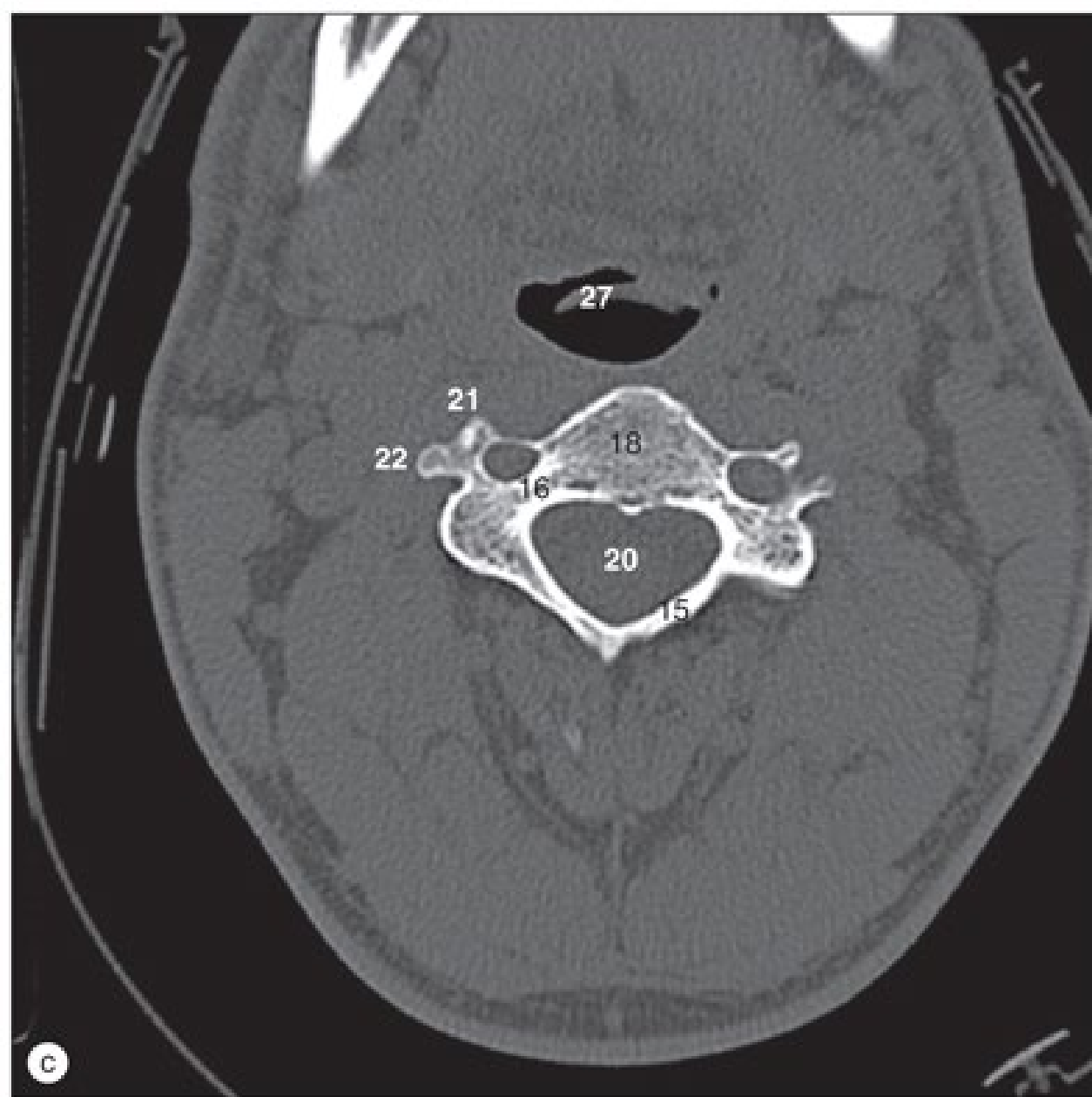


(b) Sacro e cóccix, radiografia lateral.

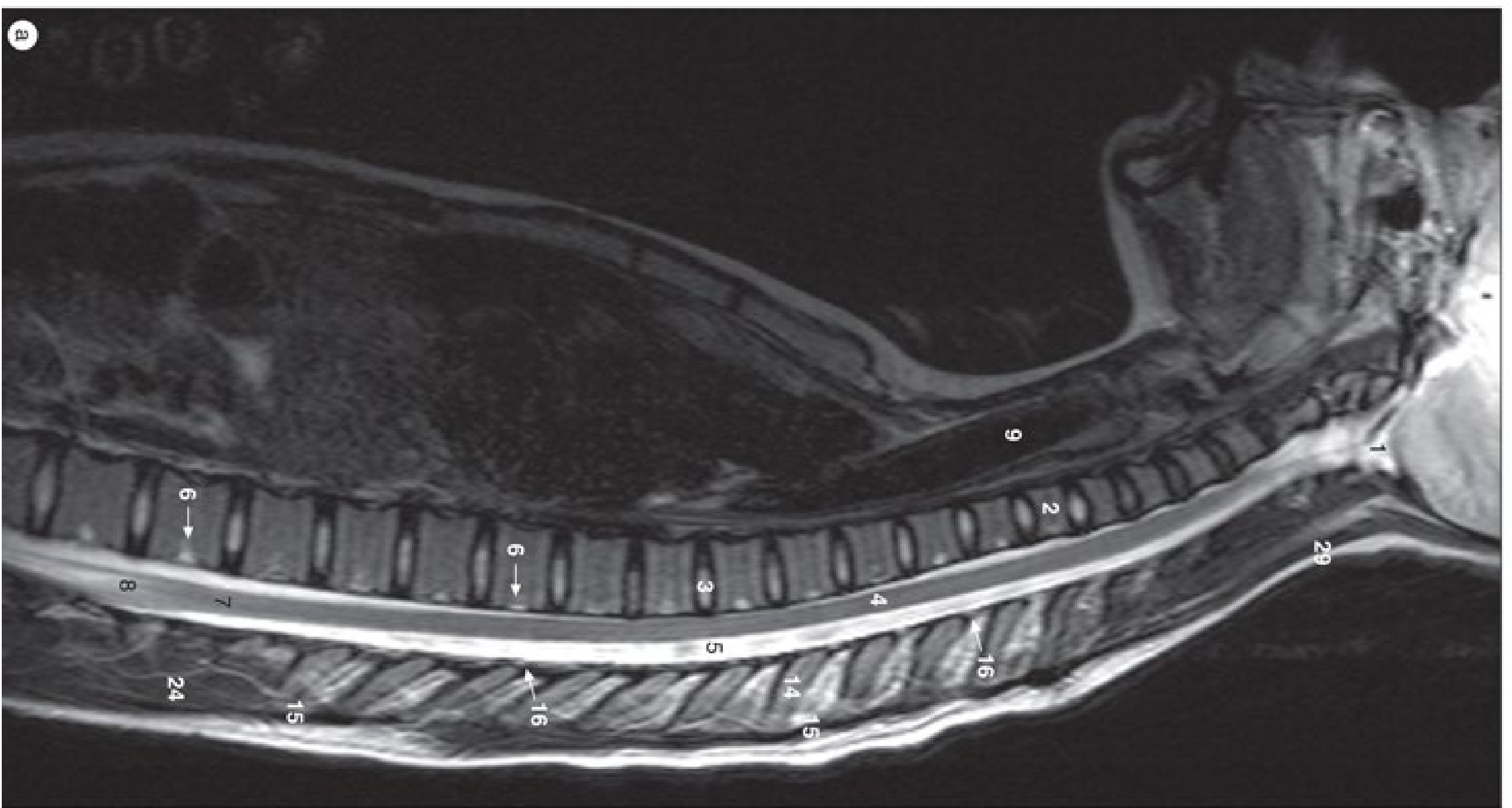


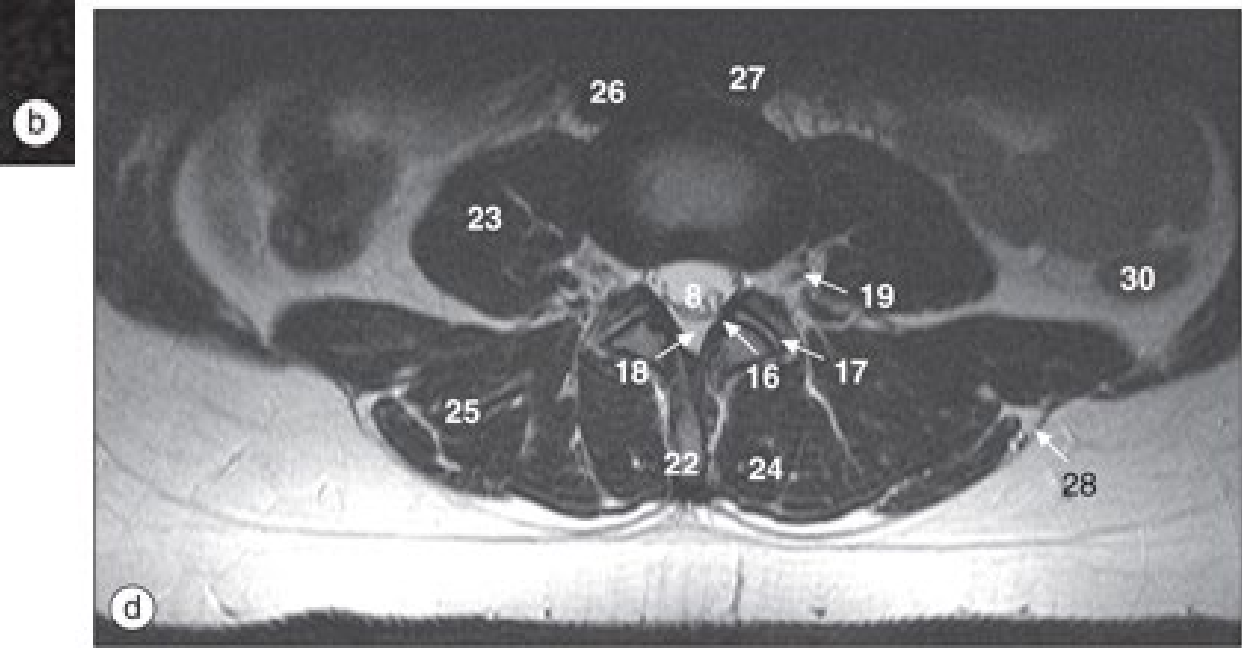
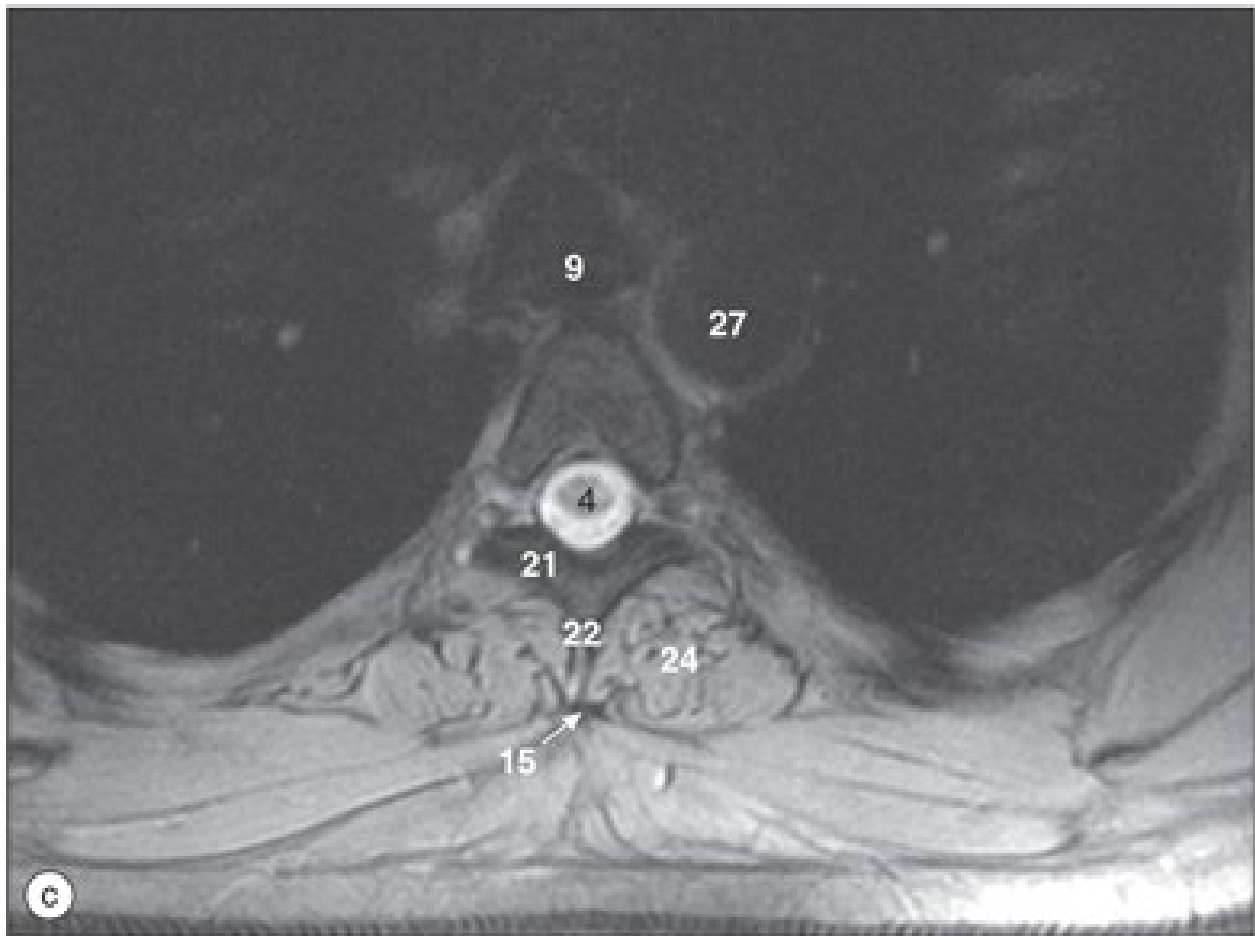
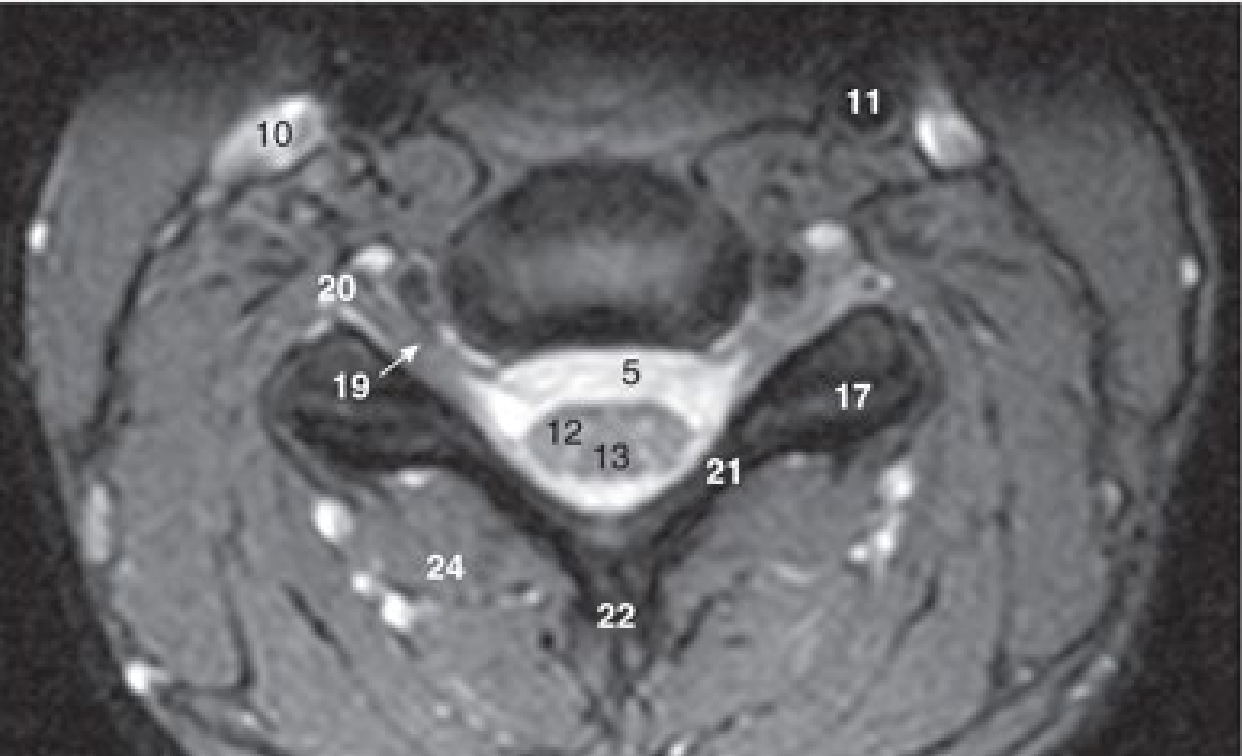


Imagens de TC axiais da coluna cervical superior nos níveis de (a, b) C1/2, (c) C2 e (d) C2/3.

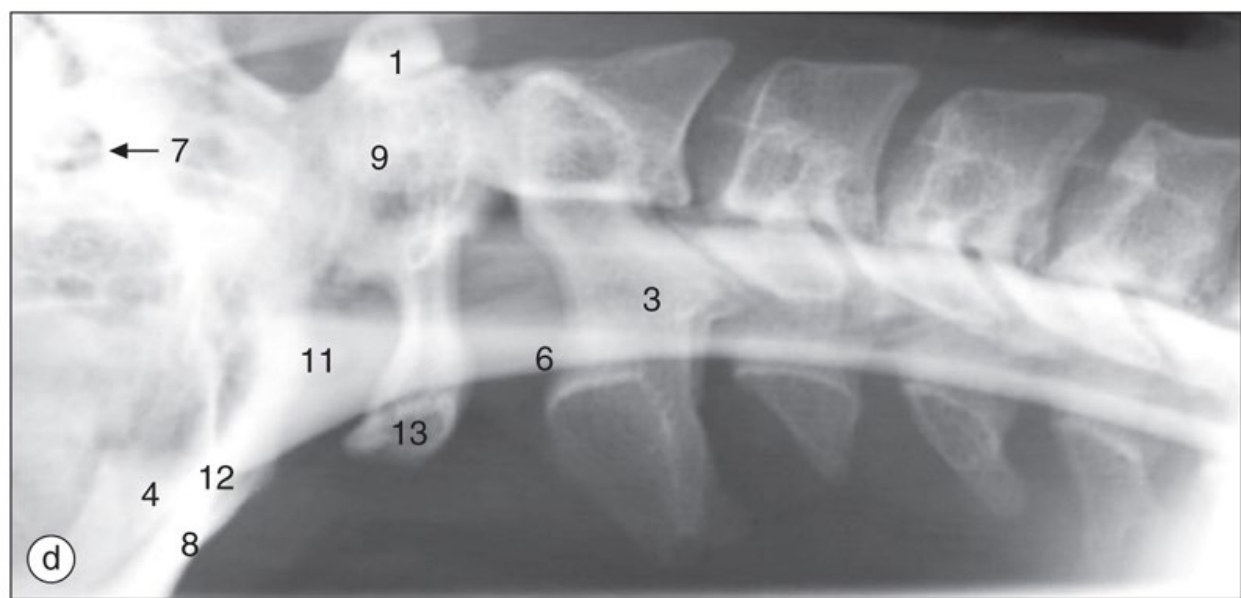
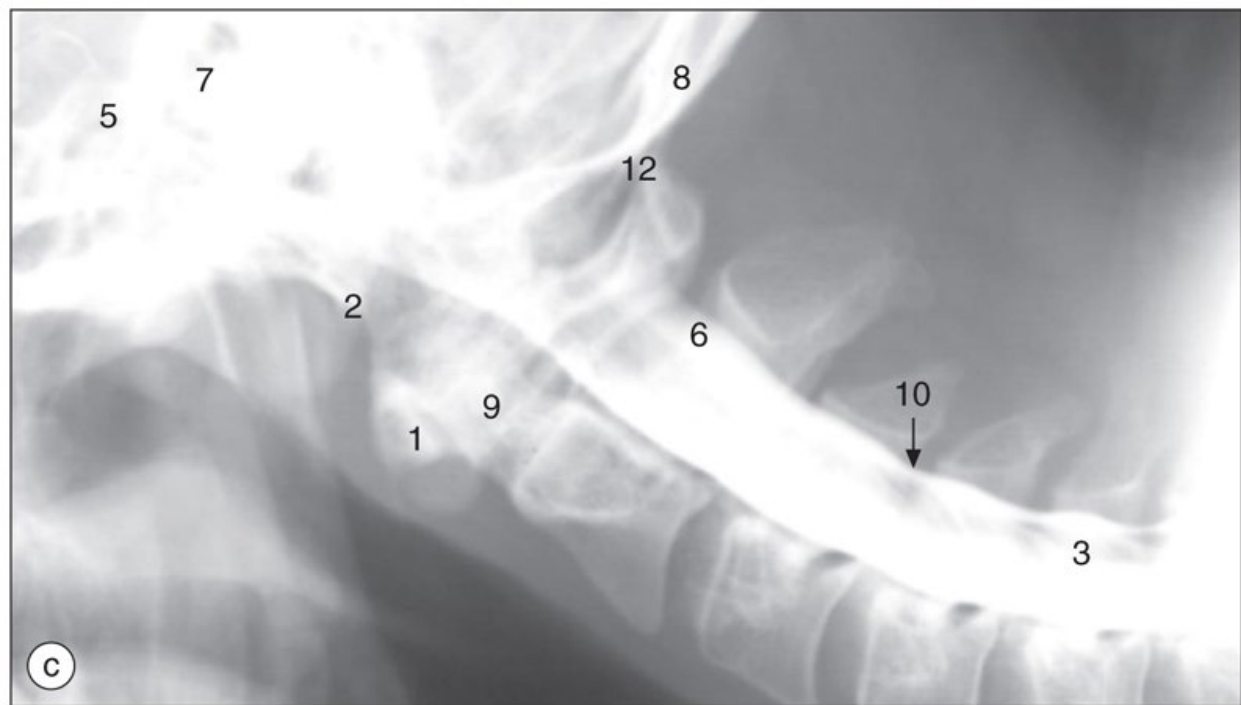
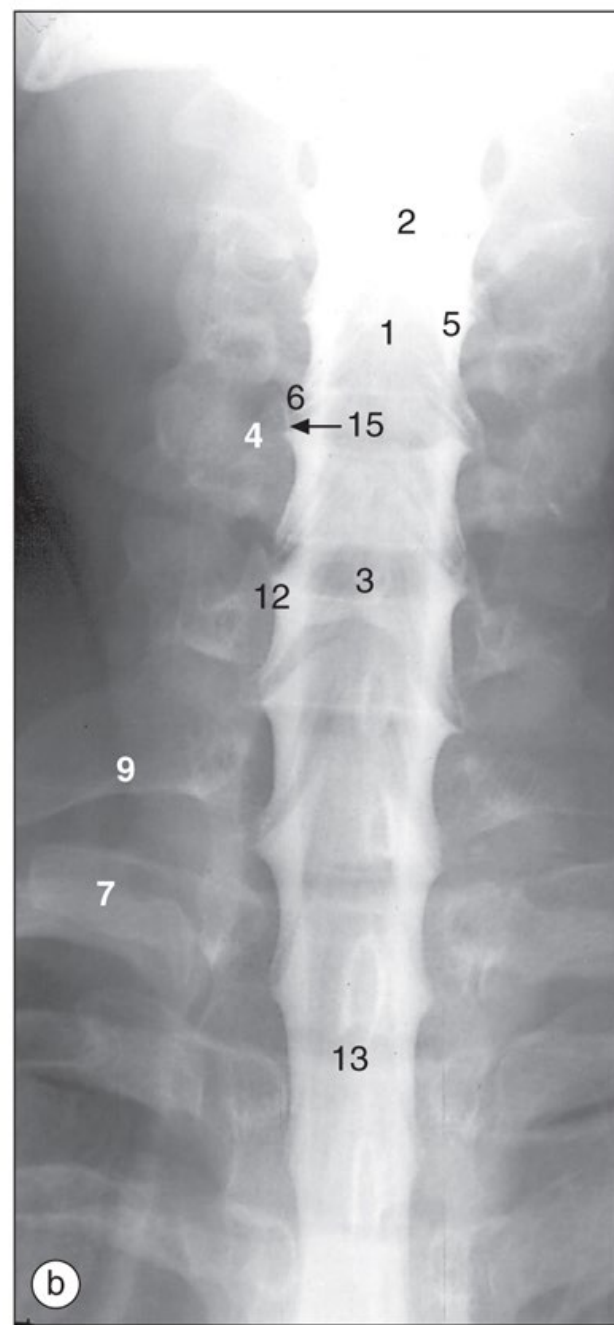
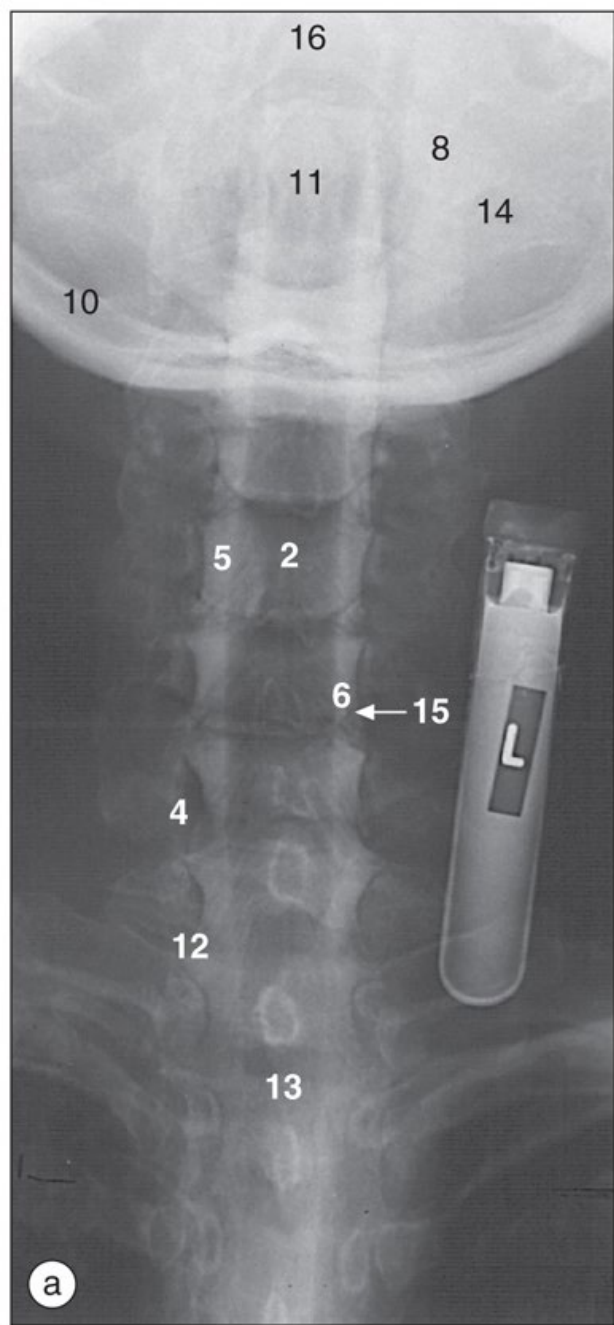


Imagens de TC axiais da coluna cervical superior nos níveis de (a, b) C1/2, (c) C2 e (d) C2/3.





Imagens de RM da coluna ponderadas em T2, (a) campo de visão sagital amplo e cortes axiais das regiões (b) cervical, (c) torácica e (d) lombar.



Mielografia cervical, radiografias anteroposteriores com o pescoço **(a)** estendido, **(b)** ligeiramente flexionado; radiografias laterais com o paciente em (c) decúbito ventral, (d) decúbito dorsal.



UniSALESIANO

