

# ANATOMIA E PATOLOGIA EM IMAGENS V

PROF FERNANDO HENRIQUE ALVES BENEDITO



**UniSALESIANO**

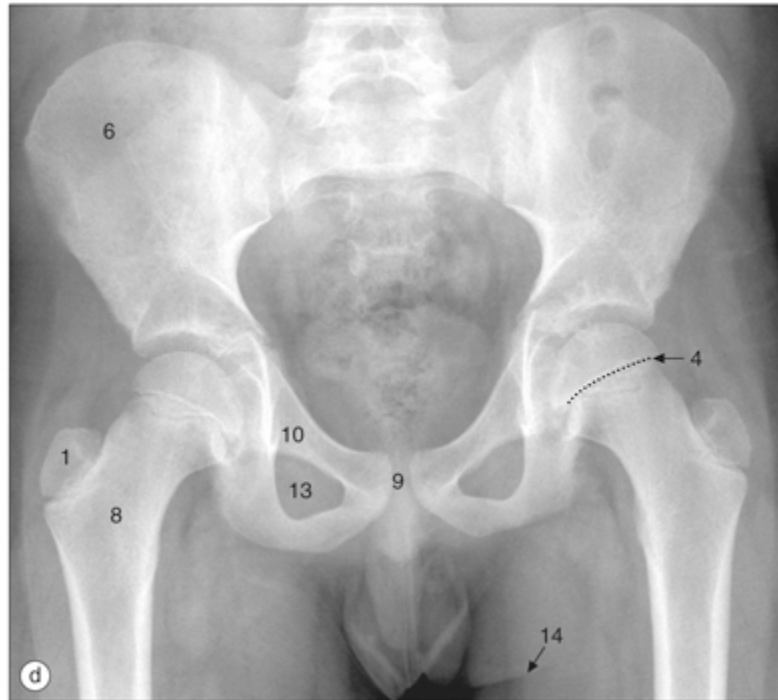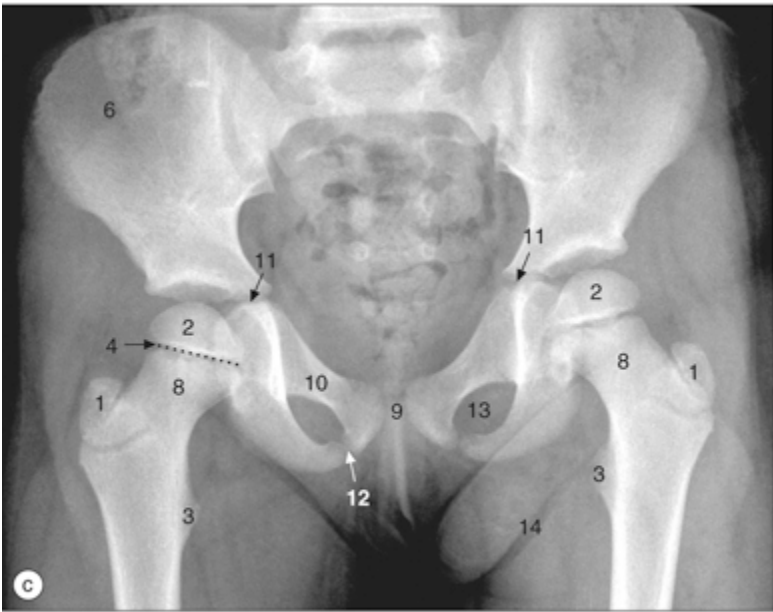
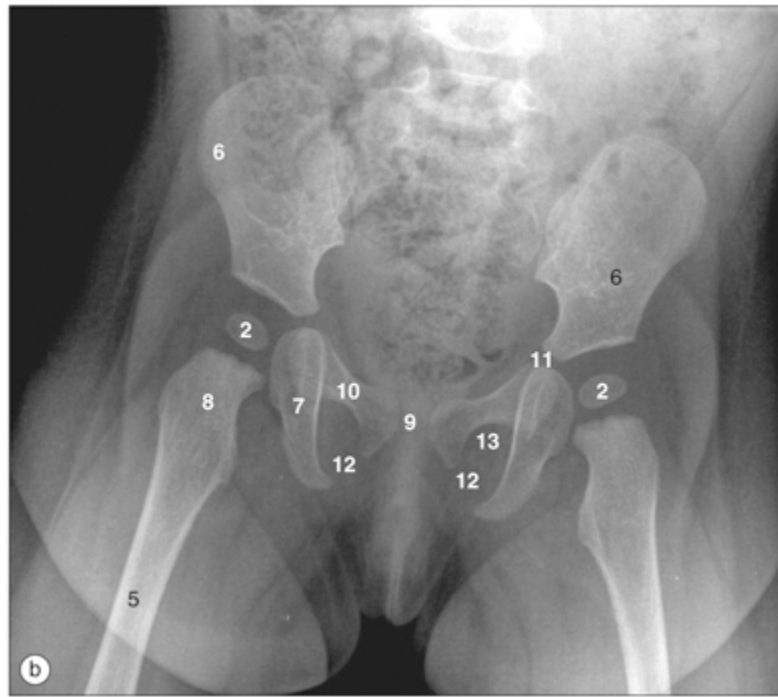
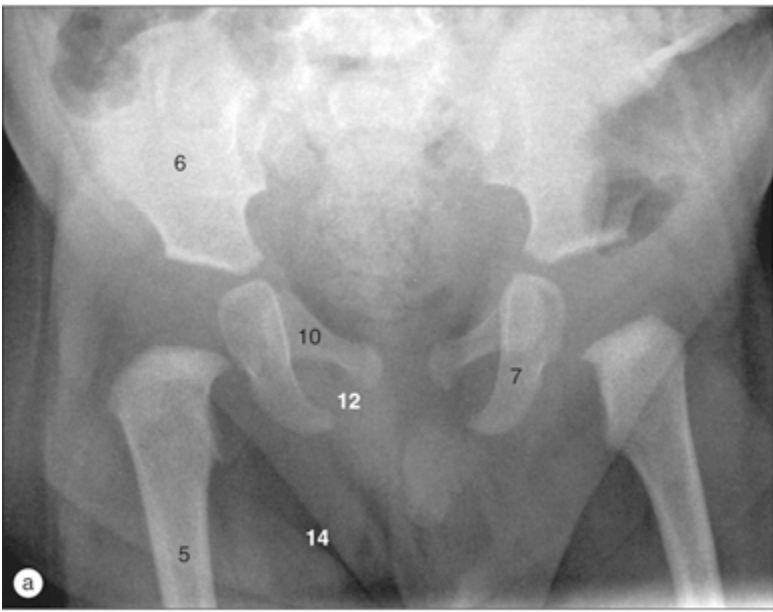


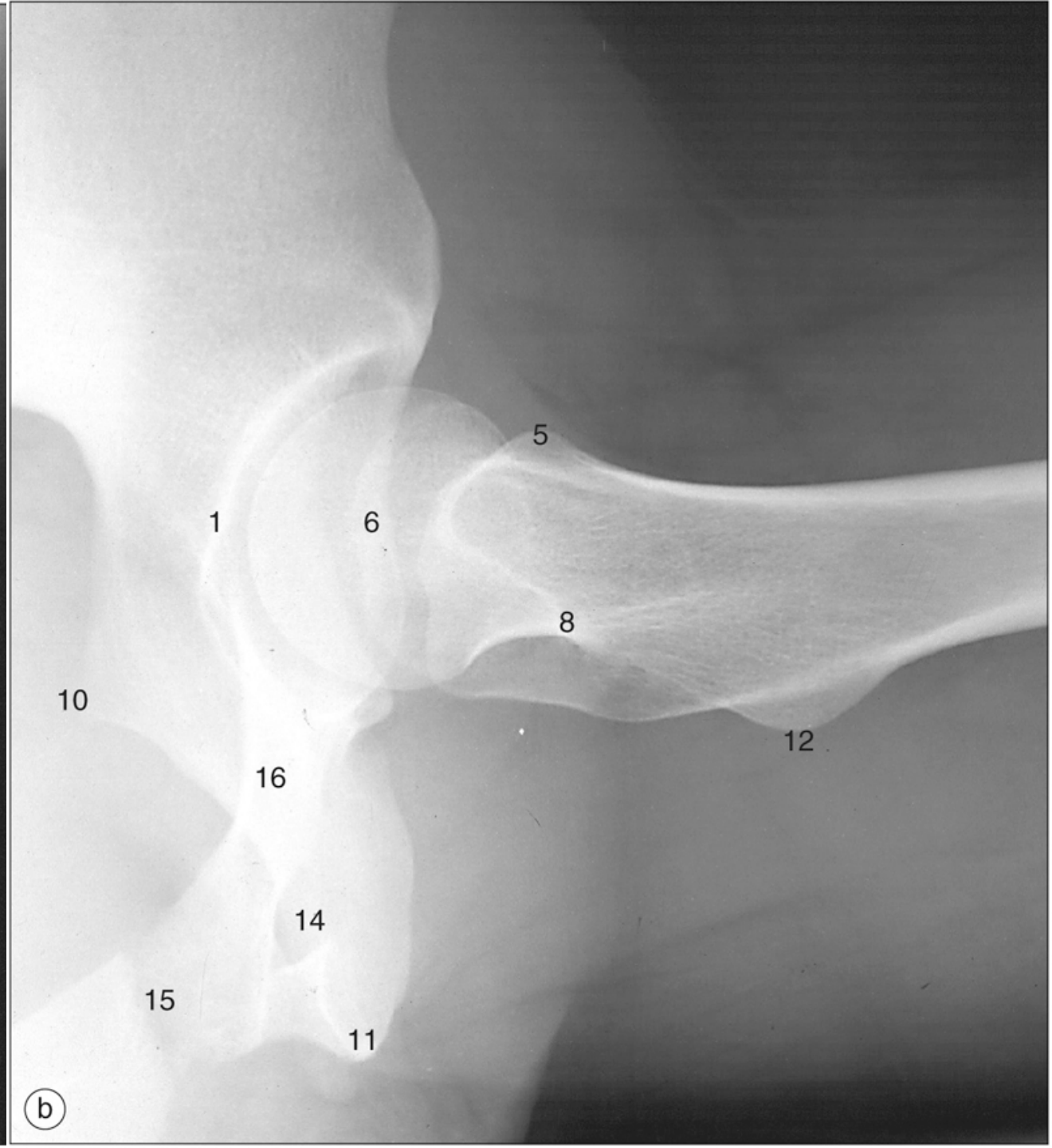
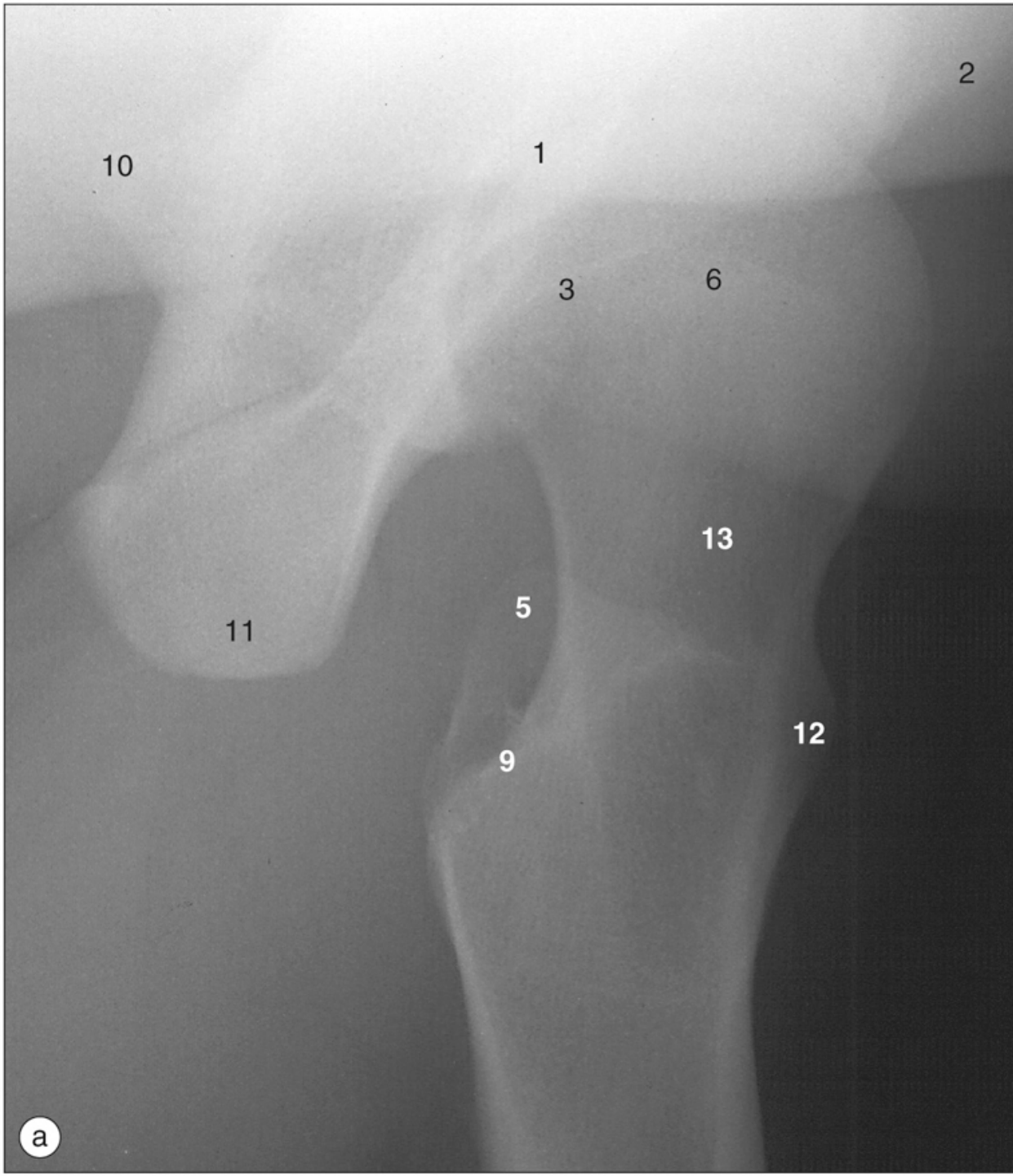
# Exames de imagens

- Encéfalo
- Crânio
- Pescoço
- Coluna vertebral
- Membro superior
- Mama e axila
- Tórax, Pulmões, mediastino
- Vasos do coração
- Abdome
- Pelve
- Ultrassonografia do abdome superior
- Ultrassonografia de abdome e pelve
- Quadril
- Membros inferiores
- Exames funcionais

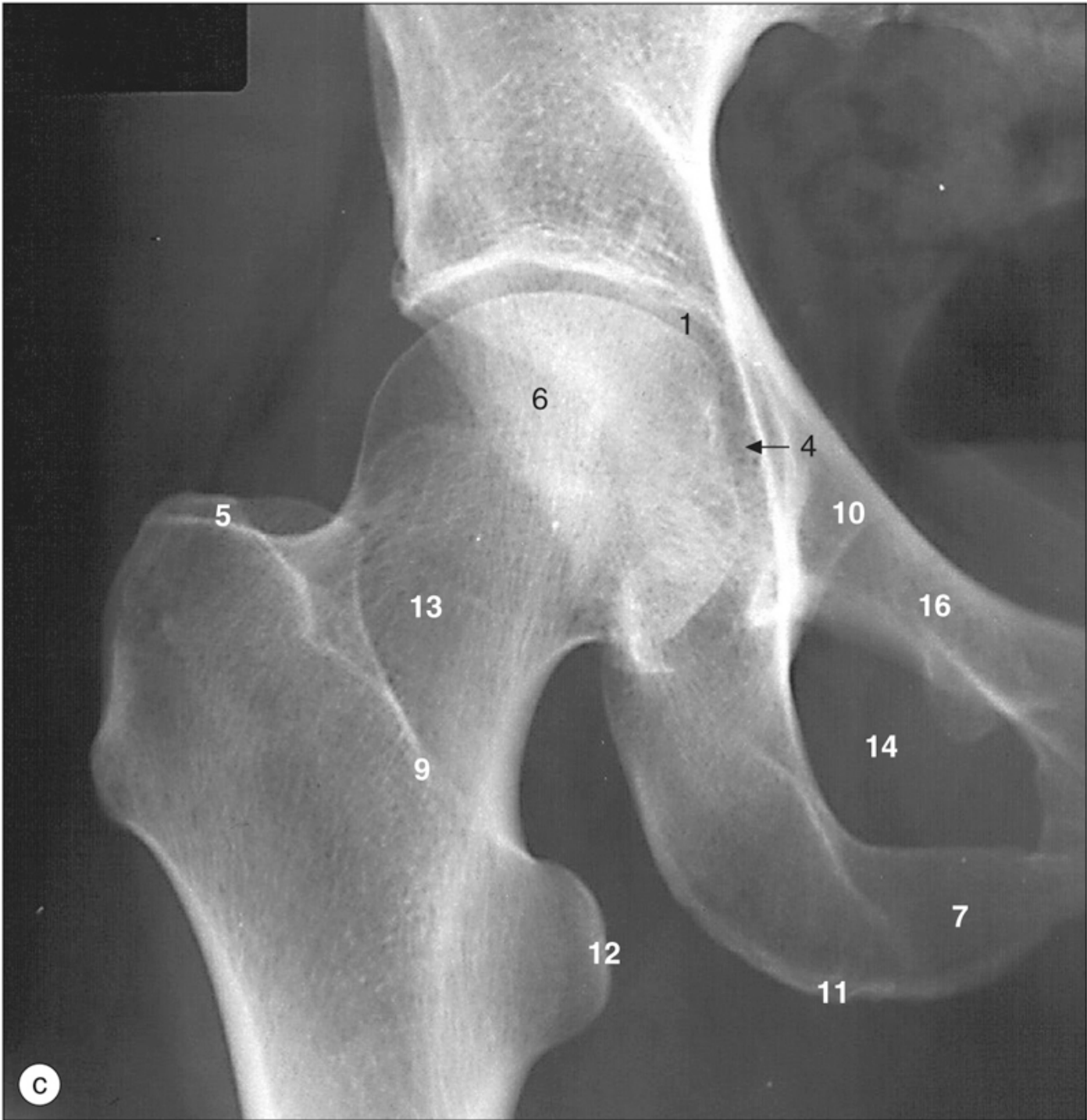# Exames de imagens

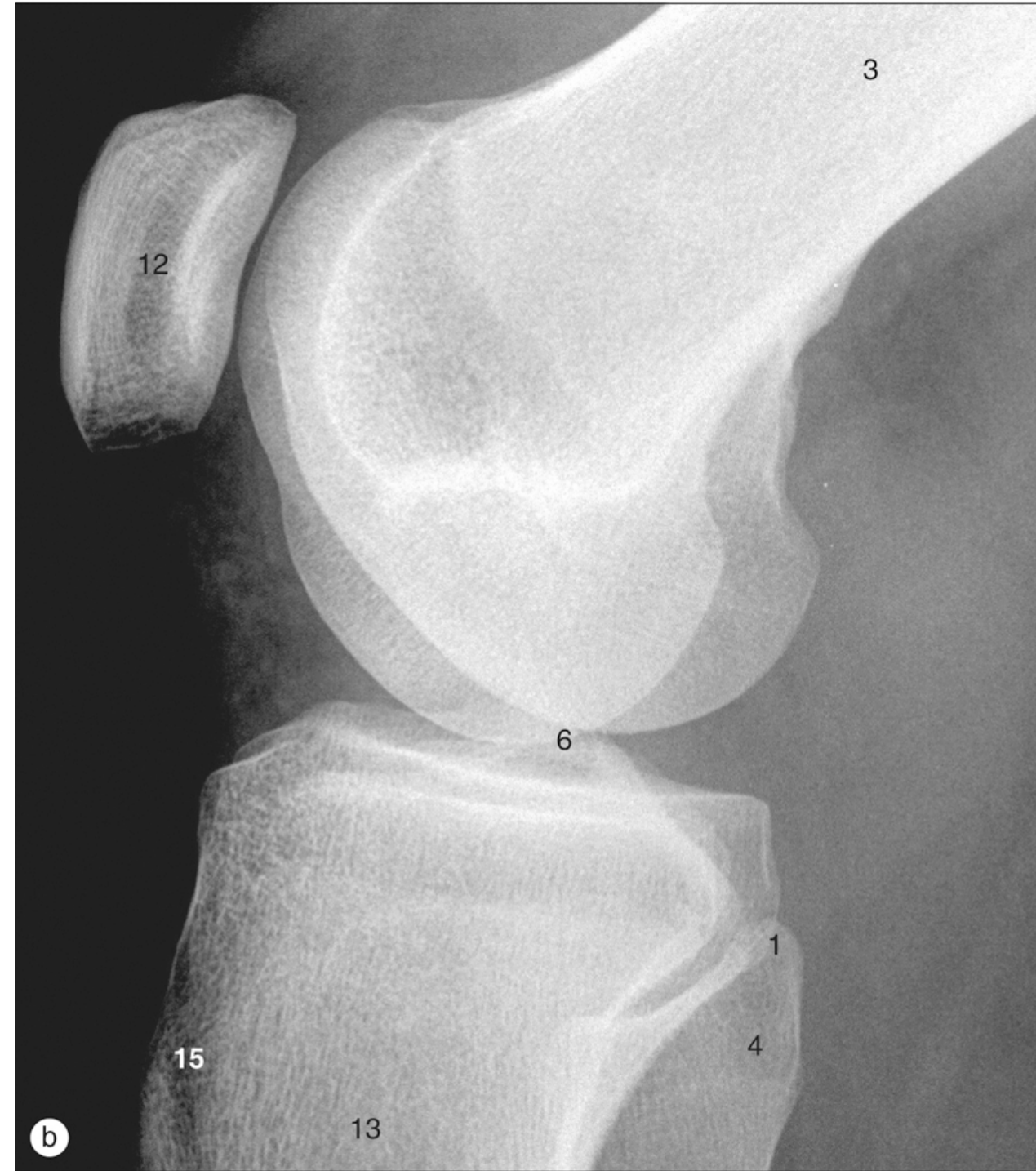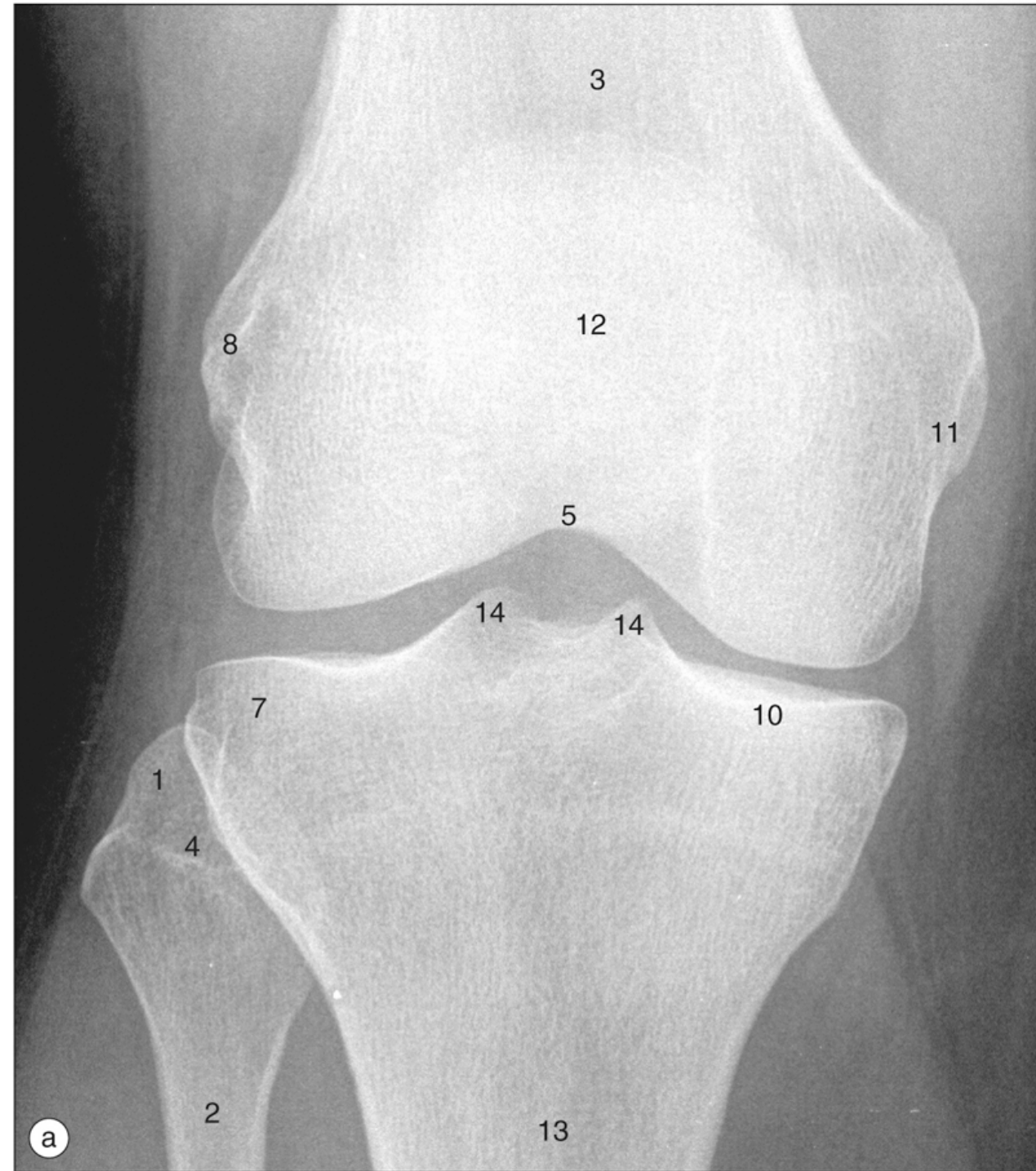
- Encéfalo
- Crânio
- Pescoço
- Coluna vertebral e medula espinhal
- Membro superior
- Mama e axila
- Tórax, Pulmões, mediastino
- Vasos do coração
- Abdome
- Pelve
- Ultrassonografia do abdome superior
- Ultrassonografia de abdome e pelve
- **Quadril**
- **Membros inferiores**
- Exames funcionais

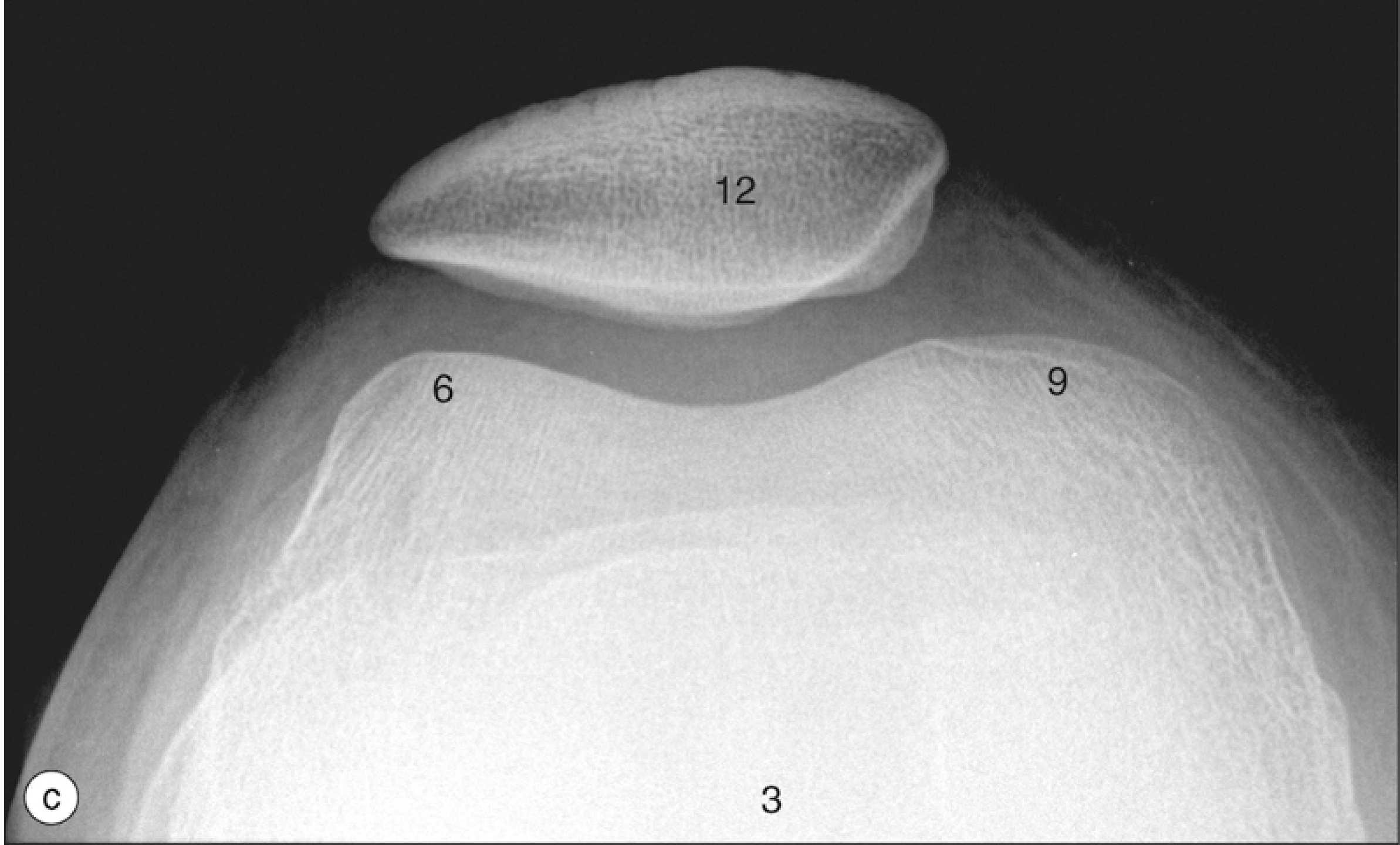




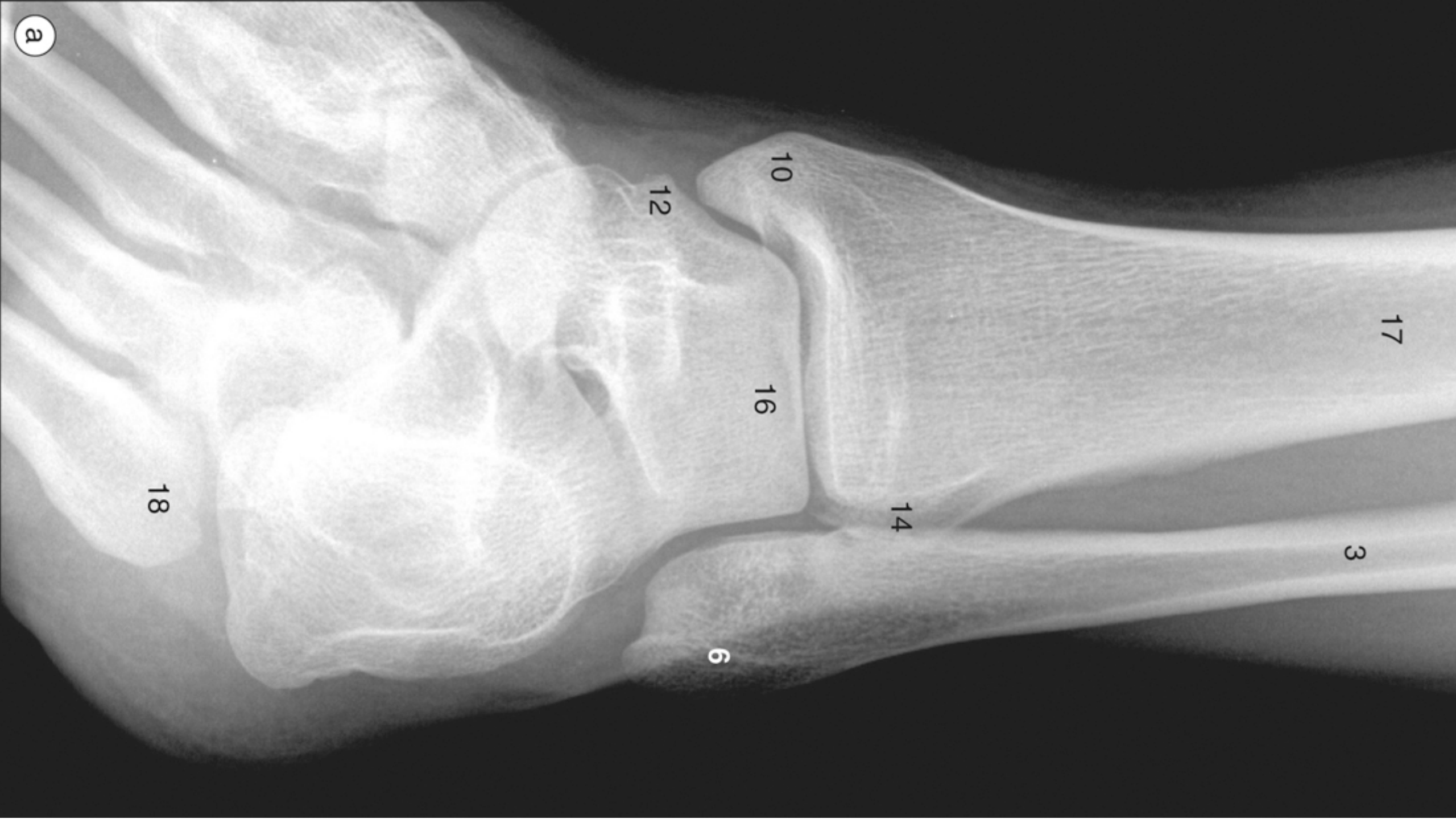


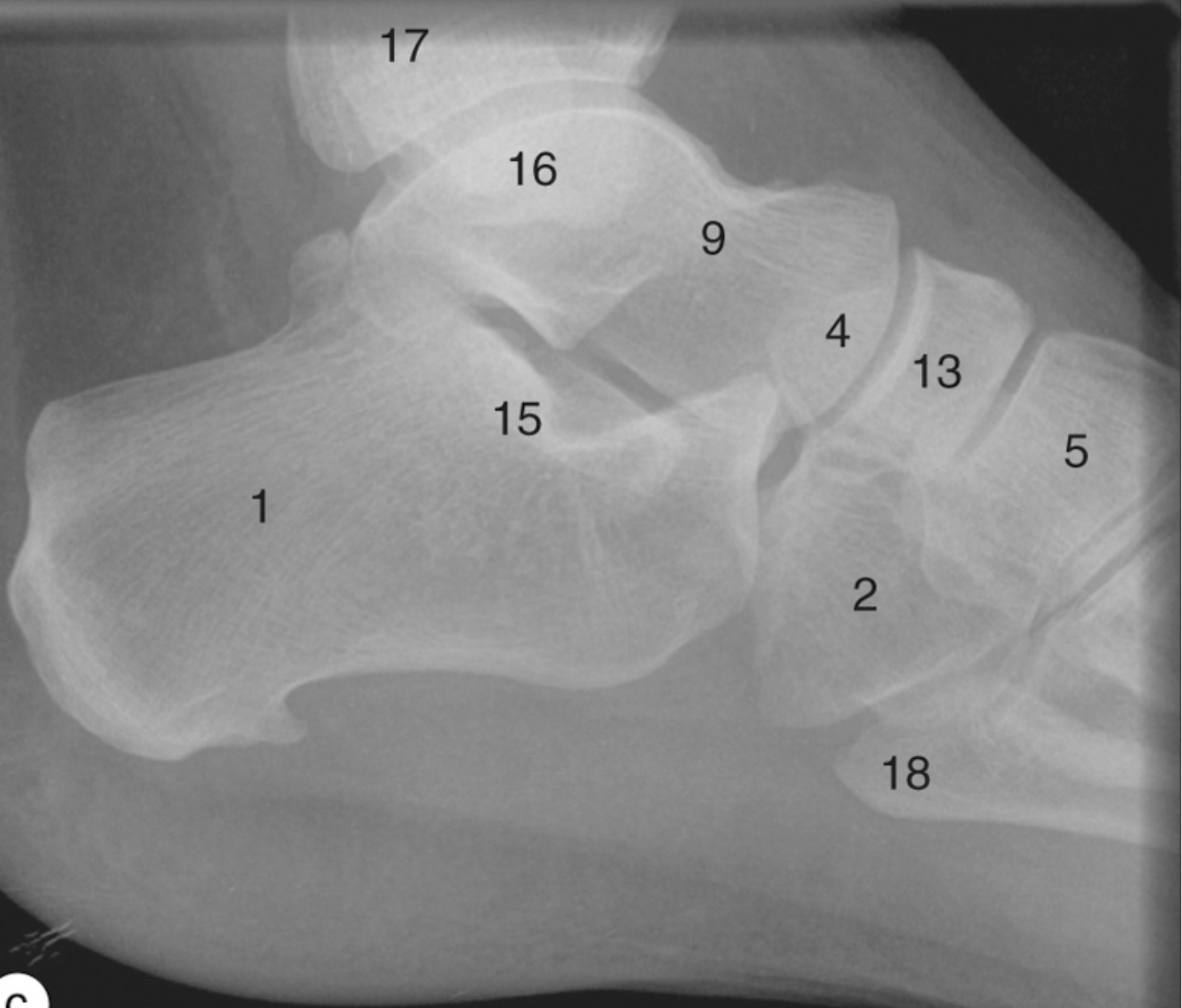


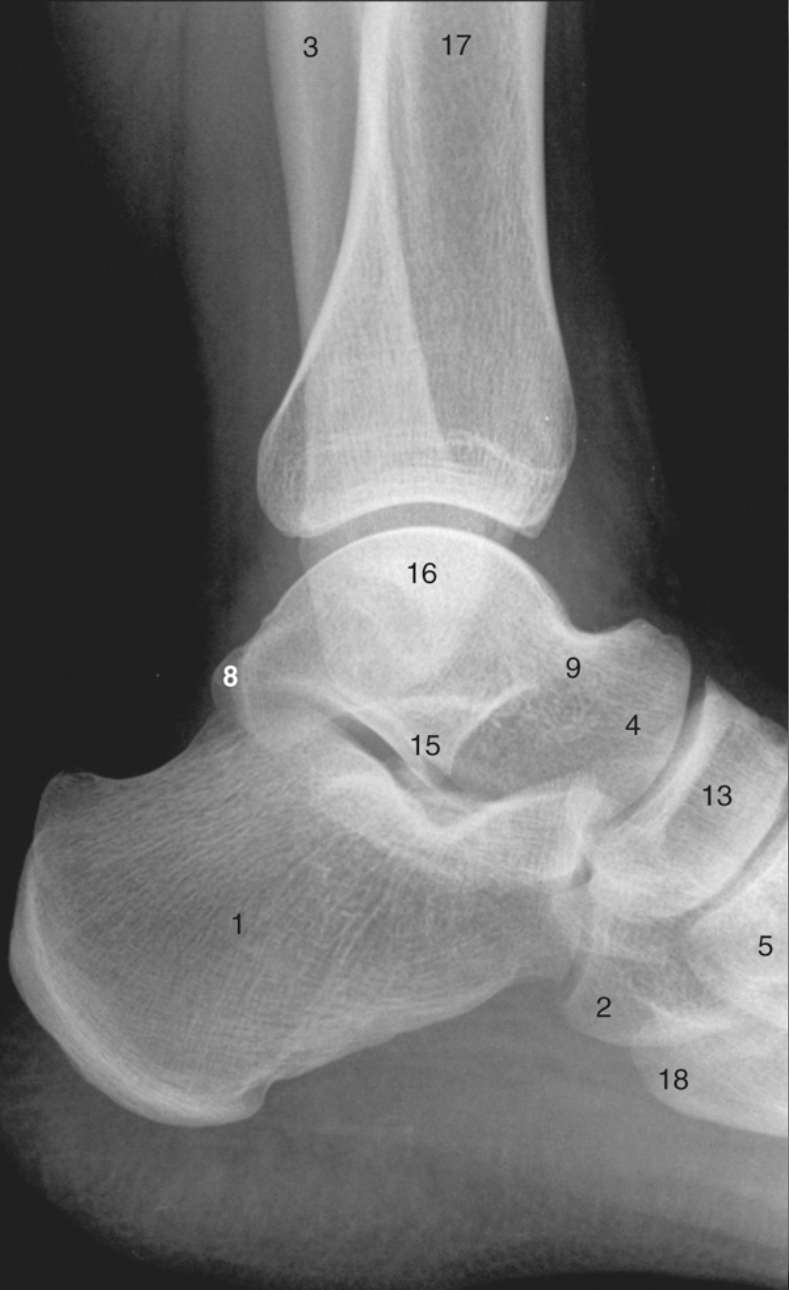


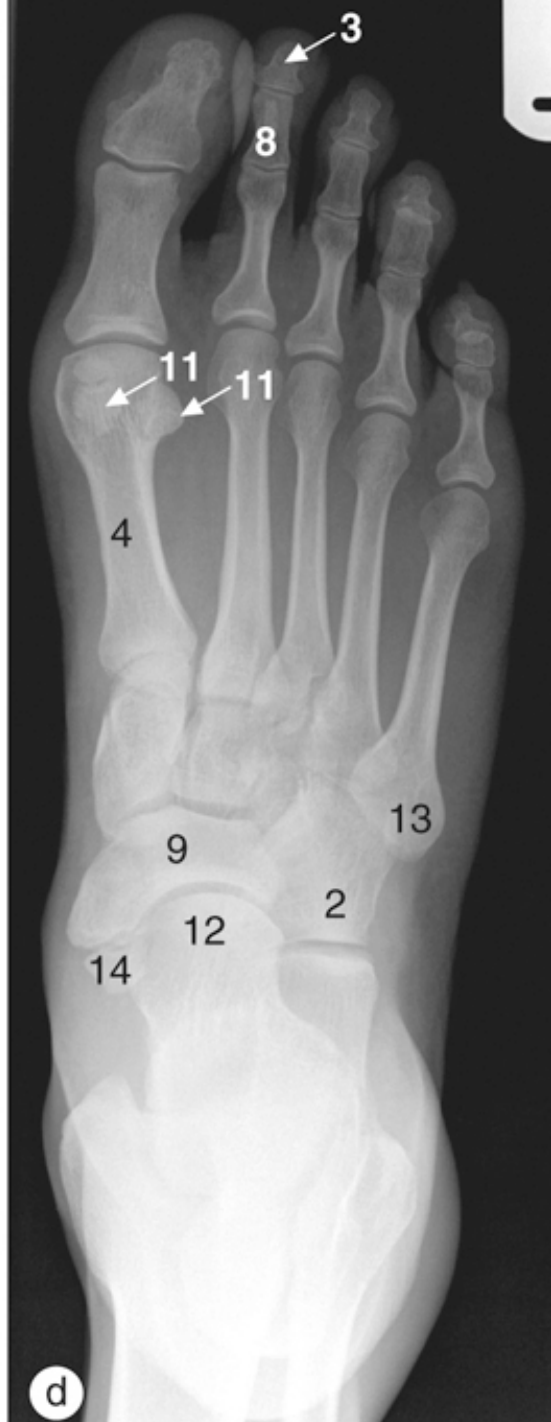
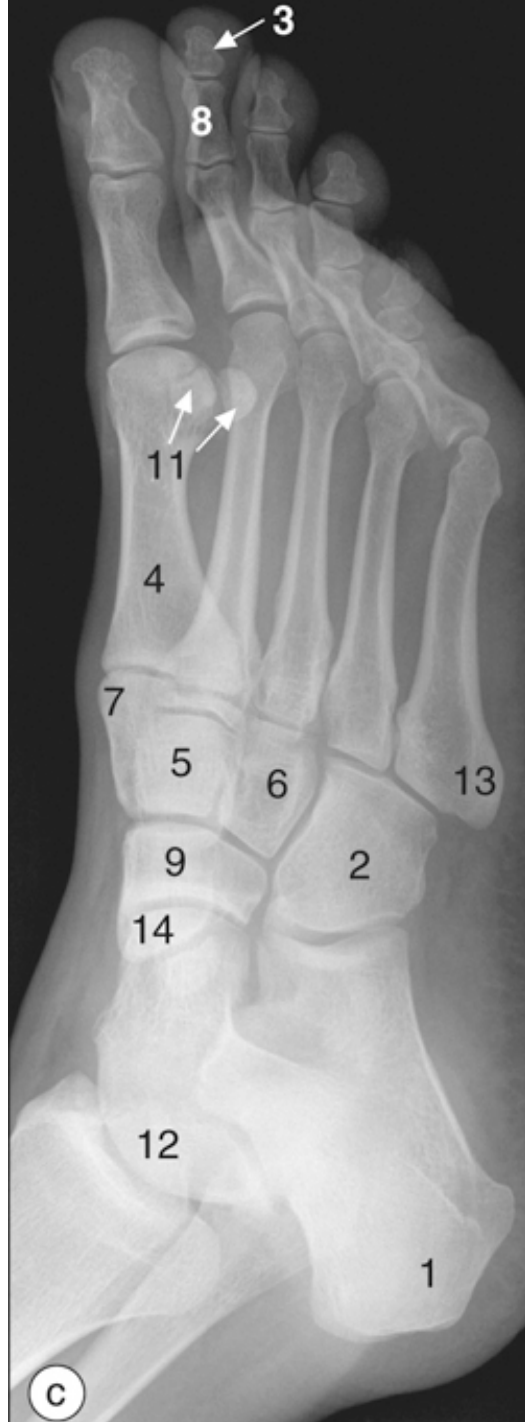
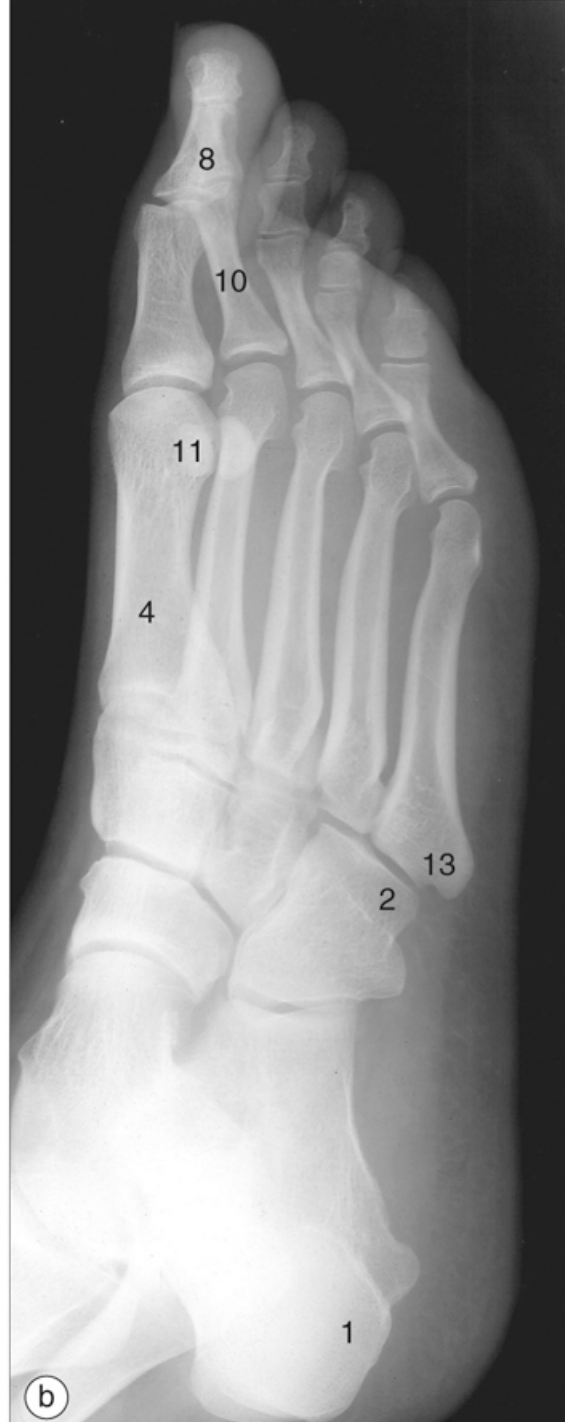
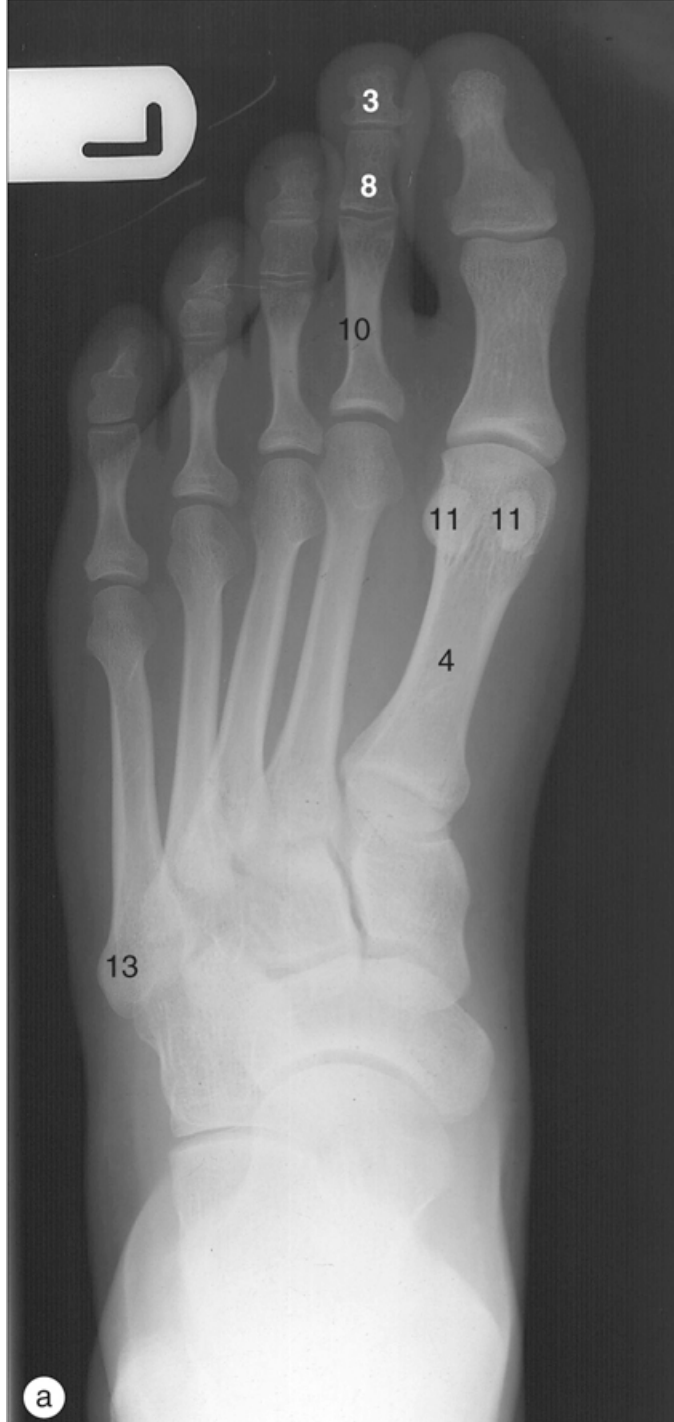a







***UniSALESIANO***

